CASE REPORT

Myomectomy and Cervical Reconstruction in an Unmarried Girl with Large Cervical Fibroid

Sudhaa Sharma, Eshwarya Jessy Kaur, Reeta Thakur, Mamta Kalsi, Sadhna Kotwal

Abstract

Leiomyomas are frequently encountered tumors in women and have a wide and varied spectrum of presentation. We report a case of large cervical fibroid in an unmarried girl, presenting with acute abnormal uterine bleeding. Such cases pose a dilemma for the doctor as fertility preservation is a significant conern for the patient.

Key Words

Cervical fibroid, Myomectomy, Cervical reconstruction

Introduction

Leiomyomas are the most common tumors of the uterus, affecting 20-50% of women. (1) Out of these, cervical fibroids comprise only 1-2% of all fibroids.(2) Depending on their location, they are classified as anterior, posterior, lateral and central. When the cervical fibroids get bigger, they may push the uterus upwards and lead to urinary retention, urinary frequency, constipation, menstrual abnormalities, dyspareunia, and sometimes post coital bleeding.(3) The diagnosis of a cervical fibroid is made with transvaginal sonography and MRI, but frequently it is made intaoperatively. (4) They can be left untreated as long as they are asymptomatic but large fibroids usually require surgery as medical and other interventional treatments like uterine artery embolization (UAE) and high intensity focused ultrasound (HIFU) usually fail by virtue of size and location of fibroids (5); myomectomy is done when fertility conservation is desired.

Case Report

A 22 year old unmarried girl presented with haemorrhagic shock and active vaginal bleeding. This was her first episode of excessive bleeding after attaining menarche at the age of 15 years with no history of menorrhagia or dysmenorrhoea since then. On admission, her pulse was 116/min, feeble , blood pressure was 70/40 mm of Hg and cold and clammy peripheries. On abdominal examination, she had a firm, smooth, relatively immobile, non tender mass of 26 weeks arising from the pelvis. Her haemoglobin on admission was 4.0 gm/dl with clotting time of 1'50", bleeding time of 5'30". Her Renal Function Tests and Liver Function Tests were within normal limits. She was resuscitated and stabilized with colloids, 3 units blood transfusions, dopamine infusion and intravenous tranexemic acid and planned for further investigations and surgery. On her 4th day of admission, she had another episode of excessive and active vaginal

From the Deptt Of Obs & Gynae, Govt. Medical College, Jammu
Correspondence to : Dr. Sudhaa Sharma, Associate Professor, Deptt of Obs & Gynae, GMC, Jammu

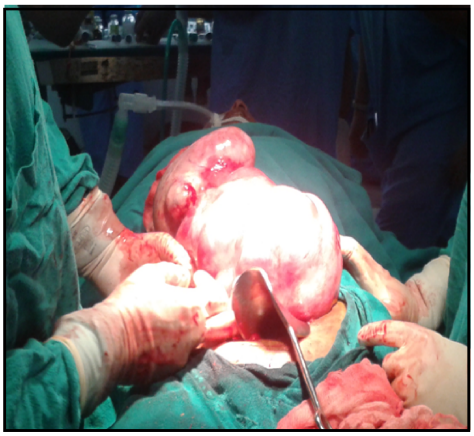

Fig 1. Fibroid with Uterus not Visualised

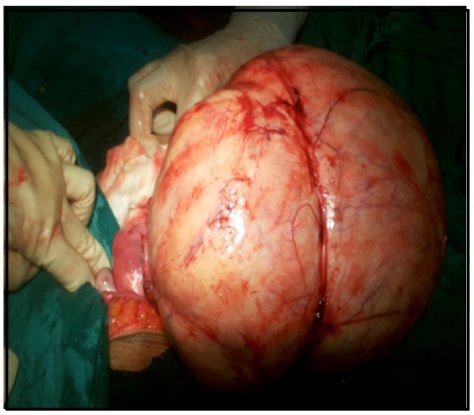

Fig 2. Fibroid with Peritoneum Stretched on it and Normal Uterus and left Ovary. (Top view)

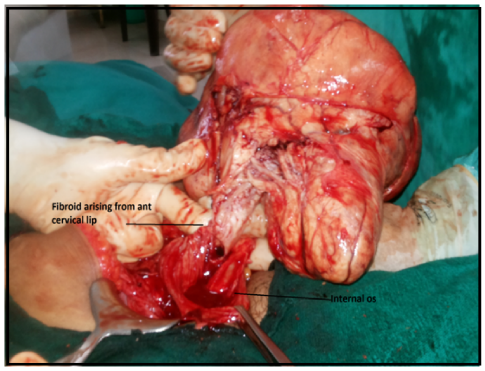

Fig 3. Origin of Fibroid from the Cervical lip

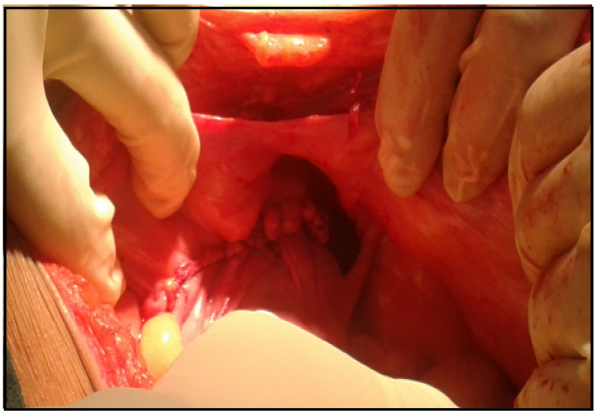

Fig 4. Cervix Reconstructed and Uterovesical Fold of Peritoneum Closed

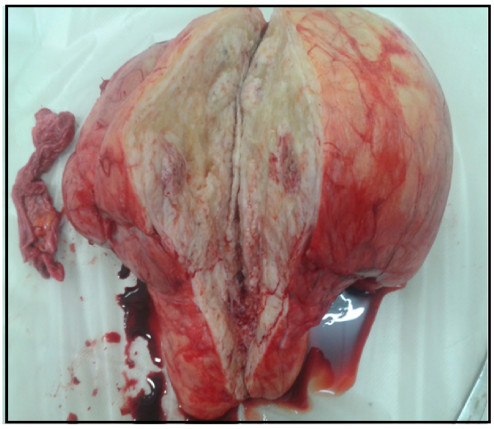

Fig 5. Cut Specimen of the Fibroid Showing the Hyaline Degenerative Changes

bleeding. A decision for emergency laparotomy was undertaken. Abdomen was opened with infraumblical midline incision. A mass of approximately 30x25 cm arising from the anterior lip of cervix was present. Uterus along with both tubes and ovaries were normal in appearance, but deviated to left side of the fibroid. The mass was adherent to gut loops posteriorly, from which it was separated by sharp dissection. Bladder was mobilised inferiorly after opening the uterovesical fold of peritoneum. The cervical fibroid was enucleated after separating the overlying capsule. The fibroid formed the bulk of the anterior lip of the cervix. The uterine cavity and the cervical canal got opened anteriorly. A hegar's dilator was introduced through the external os into the uterine cavity to see the communication of the corpus with the cervix. The dead space of myoma bed was obliterated with 1-0 and 2-0 vicryl. The anterior lip of the cervix was reconstructed in two layers with the dilator in situ with 2-0 vicryl. Redundant portion of the visceral peritoneum excised and stitched. A vaginal packing was kept to retain

the dilator in place inside the cervix. Postoperatively, the dilator was removed from the cervix on the 3rd post-op day. The patient had wound soakage on 5th day managed successfully with antibiotics. The patient was discharged on 15th post operative day. (*Fig 1-5*)

On follow up, she resumed her normal menses in 5th week after surgery, with no dysmenorrhoea or menorrhagia. A follow up ultrasound after 9 months showed anterior lip thickness of 1.5 cm and posterior lip thickness of 1.6cm with a normal endometrial thickness.

Discussion

In such large cervical fibroids, hysterectomy is the usual approach of the operating surgeon, but in cases such as these where fertility preservation is a desperate necessity for the patient, myomectomy needs to be done. The pelvic anatomy in these patients is usually distorted increasing the risk of intraoperative bladder and ureteric injuries. Very few cases have been reported with large cervical fibroids in unmarried girls. The reconstruction of cervix is a surgical challenge and the post surgery healing may be complicated by uterine cavity obliteration with adhesion formation. The resumption of menses in this patient is an encouraging sign towards her future reproductive potential.

References

1. Gupta S, Jose J, Manyonda I. Clinical presentation of fibroids. *Best Pract Res Clin Obstet Gynaecol* 2008; 22: 615e26.
2. Kumar P, Malhotra N: Tumours of the corpus uteri. In: Jeffcoat's Principles of Gynaecology. 7th Edn.; Jaypee Brothers Medical Publisher (Pvt.) Ltd. New Delhi. 2008 .pp.487-516.
3. Cheng MH, Chao HT, Wang PH. Unusual clinical presentation of uterine myomas. *Taiwan J Obstet Gynecol* 2007; 46: 323-324
4. Kim MD, Lee M, Jung DC, *et al*. Limited efficacy of uterine artery embolization for cervical leiomyomas. *J Vasc Interv Radiol* 2012 ;23(2):236-40.
5. Parker WH. Etiology, symptomatology, and diagnosis of uterine myomas. *Fertil Steril* 2007;87(4):725-36.
6. Kshirsagar SN, MM Laddad. Unusual Presentation of Cervical Fibroid: Two Case Reports. *International J Gynae Plastic Surgery* 2011;3(1):38-39.
7. Tiltman, Andrew J. Leiomyomas of the uterine cervix: A study of frequency. *International JGynecological Pathology* 1998;17(3):231-4.
8. Davies A, Hart R, Magos AL. The Excision of Uterine Fibroids by vaginal Myomectomy: A Prospective study. *Fertility Sterility* 1999;71(5):961-964.
9. Basnet N . An unusual presentation of huge cervical fibroid. *Kathmandu Univ Med J (KUMJ)*. 2005; 3 (2):173-4.