CASE REPORT

Malignant Melanona of The Nasal Cavity

Anirudh Kaul, Aniece Chowdhary, Surinder Atri

Abstract

Malignant melanomas of the Sino nasal mucosa are very uncommon, presenting frequently in advanced stages. Diagnosis becomes difficult if it is amelanotic type. A case of 80 year old male who presented with nasal mass on right side without any symptom other than difficulty in breathing and diagnosis of malignant melanoma was made on histopathology

Key Words

Malignant Melanoma, Sino Nasal Tumors, Para Nasal Sinus

Introduction

Melanomas are tumors arising from melanocytes which are neuroectodermally derived cells located in the basal layers of skin, skin adnexa and some of the mucosal membrane. Common sites for melanomas are head, neck and the lower extremities as they are exposed to sunlight, which is one of the predisposing factors. Less common sites of involvement are oral and genital mucosa, nail beds, conjunctiva, orbit, oesophagus, nasal mucosa or nasopharynx, vagina and leptomeninges (1).

Lucke first described malignant melanomas in 1869.Of all melanomas (i.e cutaneous melanomas, uveal melanoma and mucosal melanoma), primary mucosal melanomas are rare tumors and only 0.5% malignant melanomas arise in the sinonasal mucosa (2). Primary melanoma of head neck accounts for 25% to 30% of all melanomas . However the incidence of melanomas arising from mucosal surface of aero digestive tract varies from 0.4 to 4%, the majority arising in the nasal cavity or Para nasal sinuses The nasal cavity is more commonly affected than the Para nasal sinuses, and the maxillary antrum is more frequently involved than the ethmoid sinuses (3,4).

The peak age incidence is between fifth and eighth decade (4), seen slightly more commonly in males than females, although age and sex do not affect the prognosis (5,6).

Case Report

A 80 year old male presented with right sided painless nasal mass which caused difficulty in breathing for past 2 months (*Fig 1*). He did not have any other problem. Local examination revealed the presence of the brownish sessile mass in the nose on right side attached to the lateral wall of nose projecting up to the vestibule. The mass did not bleed on touch with probe. posterior rhinoscopy and indirect laryngoscopy were normal. There was no lymphadenopathy and systemic examination was normal. X-ray PNS and CT Scan of nose and PNS showed that all the sinuses on both sides were normal and neck lymhnodes were not enlarged. Routinue investigations of blood, urine ,x ray chest and ECG were normal. Patient was taken up for surgical removal of mass under general anesthesia and mass was sent for histopathology. Multiple sections examined showed a tumor of spindle and epitheloid cells arranged in nests, focal areas of necrosis and multiple foci of melanin were also identified. Mitotic figures were 2-3/HPF. The individual tumor cells showed marked pleomorphism, vesicular chromatin and occasional nucleoli. The histological features were consistant with Malignant Melanoma (*Fig.2*)

Discussion

Malignant Melanoma involving the nasal and paranasal sinus mucosa is a rare disease that is difficult to treat and generally has a poor prognosis. Next to skin and eyes, juxta mucous membrane (i.e oral mucosa, upper respiratory tract, vagina and anorectal mucosa) is most prone to malignant melanoma. Malignant melanoma comprises 5% of all nasal tumors and is second commonest malignant neoplasm (23%) in that region.

From the Department of ENT and Head Neck Surgery, SMGS Hospital & *Deptt. of Pathology, Govt.Medical College, Jammu
Correspondence to : Dr.Anirudh Kaul, Registrar, Deptt. of ENT & Head Neck Surgery, SMGS Hospital , Govt Medical College, Jammu- J&K India

Fig. 1 Photograph of 80 Year Male Patient with right Nasal Mass

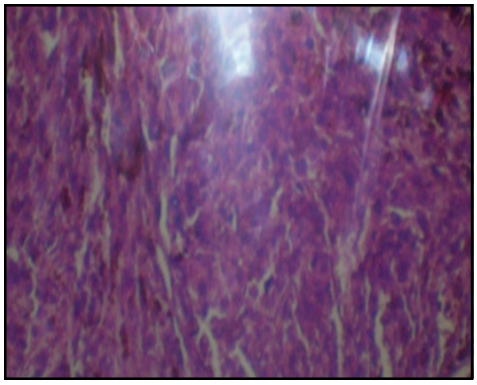

Fig.2 Shows Tumor Cells Arranged in Intersecting Fascicles Containing Melanin Pigment (H & EX100)

Median age of presentation is 63 years but can present from 50 years with a peak in the seventh decade. Both sexes are equally affected as in our case 80 year male presented with right side nasal mass dark brown in colour which turned out to be malignant melanoma on histopathology done after excision of the mass.

Usually the patients presents with epistaxis, mass or nasal obstruction (as in our case) with a mean period of 8.2 months.

On physical or gross examination, the size of the tumor varies within a wide range. In some cases the tumor was described as of the size of a pea, while as others as a large mass which has extended to the adjacent structures and destroyed the natural landmarks and osseous barriers. Two third of nasal melanomas have a dark colour, from black to brown to blue-grey, and the reminder are pink or white. The consistency may be firm, friable or cystic, and mass may be sessile, polypoid, or large obstructing lesion. They usually bleed on manuplation.

It is generally accepted that the histopathology of melanotic lesions of mucous membrane origin is no different than that of melanotic lesions occurring in the skin. The modern concepts of junctional change occurring in the stratified squamous epithelium of the skin apply to that in the squamous epithelium of pseudostratified epithelium of the nasal cavity and paranasal sinuses. Histologically their microscopic appearance is quite variable, and three general cell types are described; small polygonal, large polygonal, and spindle shaped. The nuclei are often large and vesicular, with prominent nucleoli. Multi nucleated tumor giant cells may be present. They have a higher incidence of pleomorphism and mitotic figures than their cutaneous counterparts. Malignant melanomas have melanin pigment, but it may be quite sparse. From 60% to 69% of lesions are said to contain easily visible pigment in hematoxylin-eosin stained material, while the reminder either require prolonged search of multiple sections or special stains to demonstrate pigment. The confirmation of melanoma should be achieved by the following methods: (a) the Fontana-masson stain for melanin should be positive. (b) the pigment should be bleached by potassium permanganate oxalate.(c) A stain for hemosiderin should be negative.

In differential diagnosis of primary malignant melanomas of the nose and paranasal sinuses, special care must be exercised to be certain that the tumor in question is not a metastatic melanoma or an undifferentiated carcinoma. Malignant melanoma of the nose and paranasal sinuses is usually primary.Those affecting the nose secondarily, are known, but are extremely rare. The presence of junctional changes within the mucosal epithelium should be the most valid proof that the growth is primary, but this is usually quite difficult to demonstrate (7).

As regard to treatment , surgery is the treatment of choice. Chemotherapy is at present unpromising, reports have recently surfaced in the literature supporting the use of radiation as a therapeutic modality.

References

1. Dwivedi R, Samanta N, Agarwal S. Primary Malignant Melanoma Of The Nasal Cavity And Paranasal Sinuses: A Rare Cause Of Epistaxis In The Elderly. *Internet J Of Head & Neck Surgery* 1937; 819
2. Maheshwari V, Jindal A, Ashraf M, Sharma SC. Malignant melanoma of the nasal cavity. *Ind J of Otolaryng Head Neck Surg* 56 (3). 2004: 223-24
3. McKinnon JG, Kokal WA, Neifeld JP, *et al*. Natural history and treatment of mucosal melanoma. *J Surg Oncol* 1989; 41 :222-25
4. Stern SJ, Guillamondegui O M. Mucosal melanoma of the head and neck. *Head Neck Surg* 1991; 13:22-27
5. Batsakis JG, Suarez P, Naggar AK. Pathology consultation, mucosal melanomas of the head and neck. *Ann Otol Rhinol Laryngol* 1998; 107:626-30.
6. Batsakis JG, Regezi JA, Soloman AR, Rice DH. The pathology of head and neck tumors; mucosal melanomas. *Head Neck Surg* 1982; 4:404-18
7. Snow GB, van der Waal I. Mucosal melanomas of the head and neck. *Otolaryngol Clin North Am* 1988; 19:549-64.