CASE REPORT

Ganglion Cyst of Quadriceps Tendon- A Rare Cause on Anterior Knee Pain

Chandrashekhar A. Sohoni

Abstract

A rare case of ganglion cyst of quadriceps tendon is described here. A 19-year-old male presented with left anterior knee pain of two weeks duration . The patient gave a history of trauma to the left knee joint while a wrestling match six months ago. Physical examination revealed focal tenderness just above the superior pole of patella without any obvious swelling. Magnetic resonance imaging showed a small cystic lesion within the quadriceps tendon just proximal to the superior pole of patella. Intraoperatively, the excised cystic lesion was found to be filled with gelatinous and viscous fluid. The lesion was confirmed as a ganglion cyst on histopathologic examination.

Key Words

Ganglion, Quadriceps Tendon, Magnetic Resonance Imaging (MRI)

Introduction

Ganglion cysts are commonly seen at the joints and tendons of the wrist but are rare in the region of knee joint (1). The commonest cyst in relation to the knee joint is Baker's cyst. The ganglion cyst of quadriceps tendon are very rare (2,3). Ganglion cysts are generally described as idiopathic, however, trauma has also been described as an etiology for the same. In our patient, the onset of anterior knee pain was few months after he sustained an injury to the knee joint.

Case Report

A 19-year-old male presented with left anterior knee pain of two weeks duration . The pain was more on walking and flexing the knee joint. The physical examination revealed focal tenderness just above the superior pole of patella without any swelling or other signs of inflammation. The knee joint examination was otherwise unremarkable. The patient gave a history of trauma to the knee joint while playing a wrestling match six months ago. MRI of the knee joint revealed a small multiloculated cystic lesion within the substance of the quadriceps tendon which appeared hyperintense on PDFS (*Fig.1,2,3*) and hypointense on T1W images (*Fig.4*). Small internal septations were noted within the lesion (Fig.3). Imaging findings were suggestive of a ganglion cyst. The lesion was surgically excised. Intraoperatively, the cyst was found to be filled with gelatinous and viscous fluid. No connection between the cyst and the knee joint was seen. Histopathological results confirmed the diagnosis of ganglion cyst. After surgical excision of the lesion, the patient was asymptomatic.

Discussion

The causes of knee pain are manifold. However, ganglion cyst of the quadriceps tendon is an uncommon cause of anterior knee pain. Although the development of ganglion cysts remains a debated topic whose etiology is incompletely understood, several recent histologic observations have helped elucidate their origin and ascribe it to degenerative changes. Connective tissue degeneration is characterized by several histopathological changes that are thought to result from chronic irritation,

From theDepartment Radiodignosis, NM Medical Centre, Kalyani Nagar, Pune Maharashtra- India
Correspondence to : Dr. Chandrashekhar Sohoni, B-5, Common Wealth Hsg. Soc., Opp. Bund Garden, Pune- 411001Maharashtra, India

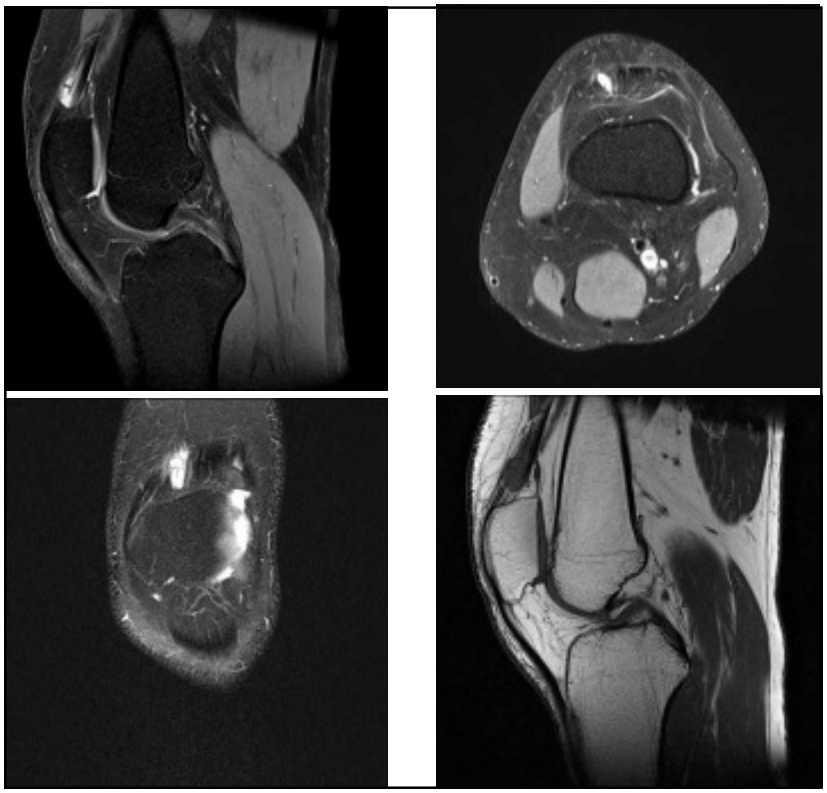

Fig .1-4 MRI Shows a Small 2.0 x 1.2 cm Cystic Lesion Within the Substance of Quadriceps Tendon on PDFS (Fig.1,2,3) and T1W (Fig.4) Images

chronic repetitive injury and chronic ischemia (4,5). Magnetic resonance imaging is an excellent noninvasive modality for localizing and characterizing ganglion cysts (1,6). On MRI, ganglion cysts originating from tendons, ligaments, tendon sheaths, menisci, or joint capsules appear as well-defined lobulated masses that follow simple or complex fluid signal intensity on all pulse sequences (6). A membranous septation within the cyst visualized on MRI is highly suggestive of the diagnosis.

Asymptomatic ganglion cysts are often left untreated. If pain or interference with activity is noted, needle aspiration or surgical excision of the lesion is considered. However, The recurrence rate of ganglion cyst after needle aspiration varies from 15% to 64%, and hence surgical excision is preferred (7).

References

1. Steiner E, Steinbach LS, Schnarkowski P, *et al*. Ganglia and cysts around joints. *Radiol Clin North Am* 1996; 34:395-425
2. Vayvada H, Tayfur V, Menderes A, *et al*. Giant ganglion cyst of the quadriceps femoris tendon. *Knee Surg Sports Traumatol Arthrosc* 2003;11:260-2
3. Lakdawala A, Ireland J. Giant ganglion formation in the quadriceps femoris tendon following total knee replacement. *Int J Clin Pract* 2004;58:990-91
4. Soren A. Pathogenesis and treatment of ganglion. *Clin Orthop Relat Res* 1966; (48):173-79
5. Kannus P, Józsa L. Histopathological changes preceding spontaneous rupture of a tendon. A controlled study of 891 patients. *J Bone Joint Surg Am* 1991; 73(10):1507-25
6. Feldman F, Singson R D, Staron R B. Magnetic resonance imaging of paraarticular and ectopic ganglia. *Skeletal Radiol* 1989;18:353-58
7. Oni JA. Treatment of ganglia by aspiration alone. *J Hand Surg [Br]* 1992; 17:660