ORIGINAL ARTICLE

# Transvaginal Sonography versus Histopathology in Postmenopausal Bleeding: A Prospective Study

**Indu Kaul, Mamta Kalsi, Amandeep K. Anand, Rekha Jad, Vinay Menia**

**Abstract**

We compared Transvaginal Sonography (TVS) with histopathological results of the dilatation and curettage biopsies in 50 women with postmenopausal bleeding attending Gynaecology out-patient department of SMGS hospital, Jammu. These women underwent TVS followed by histopathological examination of endometrium. Endometrial lesions detected by histopathology in these women were: hormonal effects (proliferative and secretary endometrium) in 5 (10%), endometrial polyps in 4 (8%), endometritis in 2 (4%), endometrial hyperplasia in 9 (18%) and endometrial carcinoma in 5 (10%). A total of 21 (42%) showed atrophic endometrium and in 4 (8%) women, sample was insufficient. On TVS, 24 (48%) women had endometrial thickness (ET) < 5 mm and 26 (52%) women had ET > 5 mm. At a cut-off limit of > 5 mm for endometrial thickness indicating pathologic endometrium, the sensitivity and specificity of TVS was 100% and 80% respectively and a predictive value as a positive test, as a negative test and accuracy was 76.9%, 100% and 89% respectively. This study shows that TVS allows detection of endometrial pathology in vast majority of women and it is relatively easy, cheap, non-invasive and does not require anesthesia. It can be used as the first diagnostic step in the investigations of women with postmenopausal bleeding.

**Key Words**

Transvaginal Sonography, Histopathology, Postmenopausal Bleeding, Endometrial Thickness

## Introduction

Postmenopausal bleeding (PMB) represents 5% of all gynecologic outpatient attendances (1). Many causes have been implicated in PMB, the commonest one being the indiscriminate use of estrogens for hormone replacement therapy (HRT). If this is excluded, PMB is caused by malignancy in 10% of all women and 30-50% of women in which there have been either continuous or repeated episodes of bleeding (2). Other possible causes include vaginal atrophy, benign and malignant neoplasms of vulva and vagina, endometrial and cervical polyps and infections.

Dilatation and curettage (D&C) is still considered gold standard for the investigation of PMB (3). This procedure has 2 main drawbacks- first it is an invasive one and has to be done under general anesthesia, so it cannot be applied repeatedly in high risk women and those with recurrent bleeding. Second, it may miss lesions such as small polyps or small endometrial carcinoma in not less than 10% of women (4).

More recently, TVS has permitted the use of higher frequency ultrasound at greater proximity to the uterus and the endometrial - myometrial interface can be seen clearly than with the full bladder transabdominal technique (5).Several studies have assessed the accuracy of TVS in evaluating the endometrium for malignancy. Measurement of endometrial thickness using TVS is helpful in diagnosis of endometrial pathology, including endometrial cancer and in assessment of myometrial invasion (6). Different cut-off levels for endometrial thickness have been used, resulting in varying degrees of reliability for detecting endometrial disease (3,7-12). The present study was designed to compare TVS findings and histopathological results of the D&C biopsy in women with PMB.

**From the Deptt. of Obst and Gyane, Govt Medical College Jammu, J&K- India**

**Correspondence to :** Dr Prof Indu Kaul, Dept. of Obstetrics and Gynecology Govt. Medical College and Associated Hospital (SMGS) Jammu-J&K

## Material and Methods

This prospective study was conducted at Dept. of Obstetrics & Gynecology, Govt. Medical College, SMGS Hospital, Jammu.

Over a period of one year, 50 women were consecutively recruited from gynecologic outpatient clinics and emergency departments for investigation of PMB according to a previously defined and tested protocol. Each patient gave informed consent to participate in the study. Inclusion criterion was women presenting with PMB. Menopause was defined as spontaneous cessation of menses for more than one year (13). The women first underwent a standard outpatient evaluation. Complete medical and surgical history including reproductive history with special attention to hypertension, diabetes, obesity, use of hormone replacement therapy (HRT), anti-estrogen therapy, anticoagulants or other therapies were recorded. A general physical examination and gynecologic examination was performed. Data was collected in a standard format for all women.

Transvaginal Sonography (TVS) was performed either on the same day or up to 3 days before the D&C. Shimasonic Shimadzo SDL310 equipped with 7.5MHz Transvaginal transducer was used for TVS. Endometrial thickness was measured as a double layer in the longitudinal plane at the widest point within the fundus with the entire endocervical and endometrial stripe visible. Uterine contour was evaluated and the presence of intramural or submucosal lesions as well as adnexial pathology was recorded. The ultrasonographic criteria considered to define normal endometrium were normal endometrial thickness (5 mm) and endometrial regularity.

Endometrial biopsy was performed by curetting the uterine cavity in clock wise or anti-clock wise direction starting from fundus down to internal os. A detailed histopathological examination of Haematoxylin and Eosin stained sections was carried out and the histopathological diagnosis was grouped in following categories: atrophy, hormonal effect (proliferative & secretary endometrium), endometrial polyp, endometrial hyperplasia, endometritis and endometrial carcinoma. Curetting sample insufficient for the histopathological examination were included in atrophy group. Atrophic and hormonally influenced endometrium was considered normal whereas other histopathological diagnosis were considered abnormal. The endometrial thickness with TVS was compared with histopathology in each case. Sensitivity, specificity, positive and negative predictive values and predictive accuracy of TVS in diagnosing endometrial abnormality at a cut-off level of < 5 mm endometrial thickness was calculated. After completing the protocol examinations, women were re-evaluated in an outpatient clinic, where data was analyzed, and were submitted to medical or surgical therapy if necessary. All procedures followed the ethical guidelines approved by the authorities of our Hospital.

## Results

The mean age of women participating in the study was 54.06 + 6.64 (range 41 to 70 years), majority being in the age group of 56-60 years. Mean age at menopause was 47.80 + 2.82 years. Majority of the women (48%) attained menopause in the age group of 47-49 years. The characteristics of the study group are listed in *Table 1*. Out of 50 women, 24 (48%) had ET < 5 mm and 26 (52%) had ET > 5 mm. Distribution of women according to endometrial thickness on TVS is shown in *Table 2*. The histopathological diagnosis of 50 women showed normal postmenopausal atrophic endometrium in 21 (42%) and hormonal effects in 5 (10%). An endometrial pathology was found in 20 (40%); endometrial hyperplasia was diagnosed in 9 (18%), a polyp was found in 4 (8%), endometritis was found in 2 (4%) and endometrial carcinoma was the histopathological report of 5 (10%). (*Fig 1*)

*Table 3* shows relationship of histopathological findings with age, parity and various risk factors. The overall risk of having abnormal pathology in women > 50 years was found to be statistically insignificant (Odds ratio 1.43 and 95% CI, 0.42%-5.06%). Abnormal histopathology was found in 12 (70.6%) women with parity < 4 as compared to 8 (24.3%) with parity > 4. This difference was found to be statistically significant (p=0.004). The overall risk of having abnormal histopathology with hypertension, obesity and diabetes mellitus was found to be statistically insignificant.

*Table 4* shows correlation of TVS with histopathology at a cut-off level of < 5 mm ET. All the 24 (48%) women with ET < 5 mm had normal endometrium on histopathology. Among 26 (52%) with ET > 5 mm, 6 women had normal endometrium (atrophy in one & hormonal effect in 5 women) and 20 women had abnormal endometrium.

At a cut-off limit of < 5 mm for ET (ET > 5 mm indicating pathologic endometrium), the sensitivity & specificity of TVS was 100% and 80% respectively. Its

*Table 1. Characteristics of Study Women*

| S. No. | Characteristics | Women (n=50) |
|---|---|---|
| 1 | Age (years) | 54.0 + 6.64 (41-70) |
| 2 | Age at menopause (years) | 47.8 + 2.82 (41-55) |
| 3 | Parity | |
| | a) Nulliparous | 2 (4%) |
| | b) Para 1 – 3 | 15 (30%) |
| | c) Para 4 – 6 | 30 (60%) |
| | d) Para 7 - 9 | 3 (6%) |
| 4 | Hypertension | 10 (20%) |
| 5 | Obesity | 8 (16%) |
| 6 | Diabetes mellitus | 6 (12%) |

*Table 2. Distribution of Women According to Endometrial Thickness on TVS*

| S. No. | ET on TVS (mm) | Women (n=50) |
|---|---|---|
| 1 | < 5 | 24 (48%) |
| 2 | 6 – 10 | 4 (8%) |
| 3 | 11 – 15 | 15 (30%) |
| 4 | 16 – 20 | 3 (6%) |
| 5 | 21 – 25 | 2 (4%) |
| 6 | 26 – 30 | 1 (2%) |
| 7 | > 30 | 1 (2%) |

*Table 4. Accuracy of TVS in Predicting Normal & Abnormal Endometrium at Cut-off Level < 5 mm ET*

| S. No. | ET on TVS (mm) | Endometrial histopathology Normal | Abnormal | Total |
|---|---|---|---|---|
| 1 | ≤ 5 | 24 (48%) | 0 | 24 (48%) |
| 2 | > 5 | 6 (12%) | 20 (40%) | 26 (52%) |
| | Total | 30 (60%) | 20 (40%) | 50 (100%) |

predictive value as a positive test was 76.9% and as a negative test was 100%. Overall accuracy and likelihood ratio was 89% and 5 respectively.

**Discussion**

In this prospective study, we had compared TVS with the D&C biopsy for detection of endometrial pathology in PMB.PMB is the presenting complaint in approximately 90% of women with endometrial carcinoma (14). However, endometrial carcinoma contributes to 10-15% of PMB and majority of women with this have no detectable organic cause (12,15). D&C still remains the usual diagnostic procedure for these women, despite inherent diagnostic limitations and the fact that it is an

*Table 3. Relationship of Age, Parity and Risk Factors with Histopathology*

| S. No. | Characteristics | Histopathology (n=50) Normal | Abnormal |
|---|---|---|---|
| 1 | Age (years) | | |
| | > 50 (n=31) | 17 (54.8%) | 14 (45.2%) |
| | < 50 (n=19) | 13 (68.4%) | 6 (31.6%) |
| 2 | Parity | | |
| | a) Para 0 – 4 (n=17) | 5 (29.4%) | 12 (70.6%) |
| | b) Para 4 – 9 (n=33) | 25 (75.7%) | 8 (24.3%) |
| 3 | Hypertension | | |
| | a) Present (n=10) | 4 (40%) | 6 (60%) |
| | b) Absent (n=40) | 26 (65%) | 14 (35%) |
| 4 | Obesity | | |
| | a) Present (n=8) | 3 (37.5%) | 5 (62.5%) |
| | b) Absent (n=42) | 27 (64.2%) | 15 (35.8%) |
| 5 | Diabetes mellitus | | |
| | a) Present (n=6) | 2 (33%) | 4 (66.7%) |
| | b) Absent (n=44) | 28 (63.6%) | 16 (36.4%) |

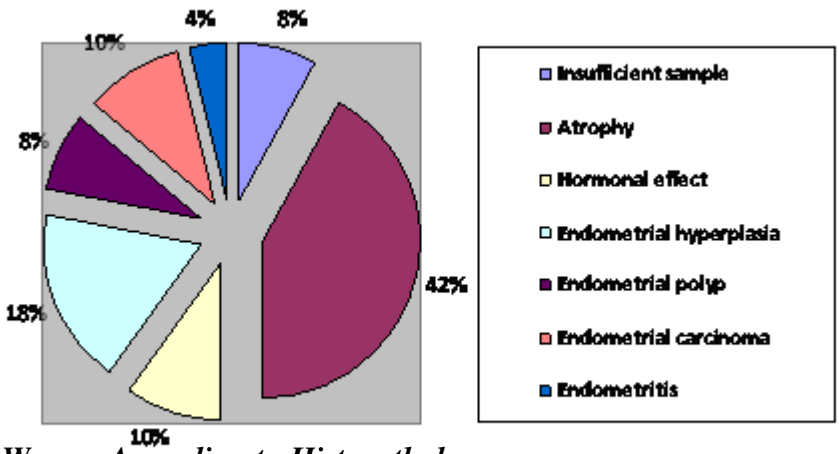


*Fig 1. Distribution of Women According to Histopathology*

invasive inpatient procedure (3,16). Furthermore, focal benign abnormalities are usually missed by this procedure and may be a source of continued or recurrent bleeding (14). The ideal diagnostic method should be cheap, safe, non-invasive and should give a rapid result.

'IVS has greatly improved resolution of ultrasound image due to the proximity of the endovaginal probe to the endometrium. The absence of the full bladder which compresses the uterus enhances this improvement and allows the measurement of the atrophic endometrium as well as detection of intracavitary lesions (5).

In our study, it was observed that after histopathology of curettings obtained by D&C, 25 (50%) women had atrophic endometrium, 9 (18%) had endometrial hyperplasia and 5 (10%) were diagnosed as endometrial carcinoma. Rest of the 11 (22%) of women were diagnosed as endometritis 2 (4%), endometrial polyp 4 (8%) and hormonally influenced endometrium 5 (10%). In a study by Goldstein SR et al, atrophy was found to be cause of PMD in 50% women and rest 50% had hormonally influenced endometrium or endometrial pathology which is in agreement to our study (17). Dia-El-Mowafi et al also found atrophy to be the cause of PMB in 45.2% of women (18). In our study, mean ET on TVS was observed as 4.00 + 1.12 mm for atrophy, 14.66 + 1.73 mm for hyperplasia and 25.0 + 5.09 mm for endometrial carcinoma when the TVS measured ET was correlated with histopathology. The mean ET for atrophy and endometrial carcinoma in a study by Karlsson B et al was found to be 3.9 + 2.5 mm and 21.1 + 11.8 mm respectively and in another study by Dia-El-Mowafi et al the corresponding values were found to be 3.8 + 1.8 mm and 21.1 + 9.8 mm (18,19). The mean ET for hyperplasia in above studies ranged between 9.7 + 2.5 mm to 15.3 + 6 mm which is comparable to our study.

Out of 50 women with PMB, 24 (48%) women had ET of 5 mm or less. Only one woman with evidence of atrophic endometrium on histology exhibited ET > 5 mm (6 mm). Out of 26 women with ET > 5 mm, 20 exhibited significant endometrial pathology. Six women with ET > 5 mm were found to be normal on histopathology. Although one patient of endometrial carcinoma presented irregular endometrial myometrial borders with variable echogenicity, there were no distinct morphologic features on TVS that could distinguish between proliferative endometrium, endometritis, hyperplastic endometrium or endometrial carcinoma.Taking 5 mm endometrial thickness as a cut-off level for detection of endometrial pathology in postmenopausal women was of good practical application in our study with an overall accuracy of 80%. This cut-off level gave false positive results in 6 women and no false negative. This agrees with Diaa EL-Mowafi et al, Grandberg S et al, Cacciatore et al and Nasri et al (5,18,20,21). For TVS the sensitivity and specificity versus endometrial pathology were 100% and 80% respectively while in Grandberg S et al study they were 100% and 96% (20). In our study, one woman with ET > 5 mm (6 mm) exhibited histopathological diagnosis of atrophic endometrium. This discrepancy is explained by the fact that this may be because of tangential measurements of ET or presence of a polyp which is often difficult to remove on curettage. Further, among 50 women presenting with PMB, 25 revealed endometrium consistent with low estrogen stimulation on histopathology,

the possible explanation for bleeding in these women being thin and atrophic menopausal endometrium. The atrophic endometrium is prone to superficial punctate ulcerations which can result in senile endometritis leading to bleeding (22).

This study shows that TVS can reach a higher sensitivity once endometrial thickness is taken into account. In addition, the presence of myometrial invasion of endometrial cancer and detection of other possible concomitant pelvic pathology can be reached (23). Since TVS is relatively cheap, easy, needs no anesthesia and non-invasive, it could be used as a first choice diagnostic test in the investigation of women with PMB. TVS can select those women in which the likelihood of endometrial pathology is high i.e. when the endometrial thickness is 5 mm or more. In these women D&C biopsy integrated by hysteroscopy should be used for achieving a proper diagnosis.

**References**


1. Moodley M, Roberts C. Clinical pathway for the evaluation of postmenopausal bleeding with an emphasis on endometrial cancer detection. *Obstet Gynecol* 2004; 24: 736-41
2. Ross L. Pelvic Ultrasound - should it be used routinely in the diagnosis and treatment of postmenopausal bleeding? *J Royal Soc Med* 1998; 81 723 - 24.
3. Büyük E, Durmusoglu F, Erenus M, Karakoc¸ B. Endometrial disease diagnosed by transvaginal ultrasound and dilatation and curettage. *Acta Obstet Gynecol Scand* 1999; 78:419-22.
4. Renaer M, Vandervoort L, Ide P, De Wolf F. Investigation of women with postmenopausal bleeding. In: Hysteroscopy. Ed. Van der Pas H. et al., MTP Press Limited, Boston, USA1983.pp. 121-28.
5. Nasri MN, Shepherd JH, Setchell ME, Lowc DG, Chard T. The role of vaginal scan in measurement of endometrial thickness in postmenopausal women. *Br J Obstet Gynecol* 1991; 98:470
6. Cacciatore B, Ramsoy T, Lehtoirta P, Ylostalo P. Transvaginal sonography and hysteroscopy in postmenopausal bleeding. *Acta Obstet Gynecol Scand* 1994; 73: 413 - 16.
7. Tahir MM, Bigrigg MA, Browning JJ, Brookes ST, Smith PA. A randomised controlled trial comparing Transvaginal ultrasound, outpatient hysteroscopy and endometrial biopsy with inpatient hysteroscopy and curettage. *Br J Obstet Gynaecol* 1999; 106: 1259-64.
8. Bakour SH, Dwarakanath LS, Kahn KS, Newton JR, Gupta JK. The diagnostic accuracy of ultrasound scan in predicting endometrial hyperplasia and cancer in postmenopausal bleeding. *Acta Obstet Gynecol Scand* 1999; 78:447-51.
9. Haller H, Matejcic N, Rukavina B, Krasevic M, Rupcic S, Mozetic D. Transvaginal sonography and hysteroscopy in women with postmenopausal bleeding. *Int J Gynaecol Obstet* 1996; 54: 155-59.
10. Loverro G, Bettochi S, Cormio G, *et al*. Transvaginal sonography and hysteroscopy in postmenopausal uterine bleeding. *Maturitas* 1999;33: 139-44.
11. Gull B, Carlsson S, Karlsson B, Ylöstalo P, Milsom I, Granberg S. Transvaginal ultrasonography of the endometrium in women with postmenopausal bleeding: is it always necessary to perform an endometrial biopsy? *Am J Obstet Gynecol* 2000; 182: 509-15.
12. Briley M, Lindsell DRM. The role of transvaginal ultrasound in the investigation of women with post-menopausal bleeding. *Clin Radiol* 1998; 53: 502-05.
13. Rita S, Margarida S, Luis L, *et al*. Transvaginal ultrasonography and Hysteroscopy in postmenopausal bleeding: A prospective study. *Acta Obstet Gynecol Scand* 2001; 80: 856-62
14. Lurain JR. Uterine cancer. In: Berek JS, Adashi EY, Hillard PA (eds.): Novak's Gynecology. 12th ed. Baltimore: Williams & Wilkins, 1996.pp. 1057-110.
15. Giusa-Chiferi MG, Gonc¸alves WJ, Bacarat EC, Albuquerque Neto LC, Bortoletto CC, Lima GR. Transvaginal ultrasound, uterine biopsy and hysteroscopy for postmenopausal bleeding. *Int J Gynaecol Obstet* 1996; 55: 39-44.
16. Weber G, Merz E, Bahlmann F, Rösch B. Evaluation of different transvaginal parameters in women with postmenopausal bleeding. *Ultrasound Obstet Gynecol* 1998; 12:265-70.
17. Goldstein SR, Nachtigall M, Synder JR, *et al*. Endometrial assessment by vaginal ultrasonography before endometrial sampling in patients with postmenopausal bleeding. *Am J Obstet Gynecol* 1990; 163:119-23
18. Diaa El-Mowfi, Ahmed F, Ahmed El B. Transvaginal sonography and hysteroscopy versus histopathology in postmenopausal bleeding. Geneva Foundation for Medical Education & Research. 2003- Draft Document.
19. Karlsson B, Granberg S, Wickland M, *et al*. Transvaginal ultrasonography of the endometrium in women with post menopausal bleeding-A Nordic multicentre study. *Am J Obstet Gynecol* 1995; 172:1488-94
20. Grandberg S, Wickland M, Karlsson B. Endometrial thickness as measured by endovaginal ultrasound for identifying endometrial abnormalties. *Am J Obstet Gynecol* 1991;164: 47 52.
21. Cacciatore B, Ramsoy T, Lehtoirta P and Ylostalo P. Transvaginal sonography and hysteroscopy in postmenopausal bleeding. *Acta Obstet Gynecol Scand* 1994; 73: 413 - 16.
22. Lau TK, Chung TKH, Haines CJ. Preliminary study on the effect of hormone replacement therapy on peripheral flow velocity in postmenopausal women. Maturitas 1997; 26(1): 53-56
23. Goldstein S. Use of ultrasonohysterography for diagnosis of perimenopausal patients with unexplained uterine bleeding. *Am J Obstet Gynecol* 1994; 170: 565 70.