

**CASE REPORT**

Extrathoracic Lung Herniation From Blunt Trauma Chest

Harish Matta , Prabhdeep Singh Nain, Kuldip Singh

Abstract

Traumatic extrathoracic lung herniation is an exceptional complication of blunt trauma chest. We report a case of 44-year-old man who sustained severe blunt trauma chest with multiple rib fractures in a motor vehicle collision and the diagnosis was established through Computerised Tomographic scan chest. Patient was managed by standard posterolateral thoracotomy and a separate incision over the herniated part anteriorly to facilitate the reduction of herniated segment of the lung. Patient had an uneventful recovery.

Key Words

Traumatic, Extrathoracic, Lung Herniation

Introduction

Traumatic extrathoracic lung herniation is an exceptional complication of blunt trauma chest (1). We report a case of 44-year-old man who sustained severe blunt trauma chest with multiple rib fractures in a motor vehicle collision and the diagnosis was established through Computerised Tomographic scan chest. Patient was managed by standard posterolateral thoracotomy and a separate incision over the herniated part anteriorly to facilitate the reduction of herniated segment of the lung. Patient had an uneventful recovery.

Case Report

A 44-year-old overweight (106kg) man with past history of obstructive sleep apnoea was involved in a motor vehicle collision, presented in emergency with history of increasing dyspnoea, and a right sided chest pain made worse by coughing. On admission patient was conscious, vitals signs were blood pressure of 110/70 mm Hg with pulse of 90 per min, respiratory rate of 34/min and SPO2 of 95% on high flow oxygen inhalation. On chest examination, showed bruising on chest wall

with generalized wheeze and surgical emphysema. A tender area of paradoxical movement of the chest wall overlaid the lower ribs in the right mid-axillary line, with underlying crepitus. Arterial Blood Gas Analysis shows acidosis with hypoxia and CO2 retention. Plain radiography of the chest showed multiple rib fracture with subcutaneous emphysema. On basis of chest X-ray findings, intercostal tube was inserted on the right side, immediately output of 500 ml of hemorrhagic fluid was obtained in chest bag. After the initial resuscitation and stabilization patient was shifted to intensive care unit for further management. On next day chest tube output was 500 ml frank hemorrhagic fluid with stable vitals with suspicion of lung contusion on chest X-ray, thus the patient was planned for Contrast Enhanced CT chest. There is evidence of multiple rib fracture on right side with herniation of part of right upper lobe into soft tissue chest wall, moderate amount of pleural effusion with basal consolidation on right side, pneumomediastinum with subcutaneous emphysema (*Fig 1*).

From the Department of Surgery , DMCH, Ludhiana, Punjab India

Correspondence to : Dr. Harish Matta, Associate Professor, Dept. of Surgery, DMCH, Ludhiana, Punjab- India

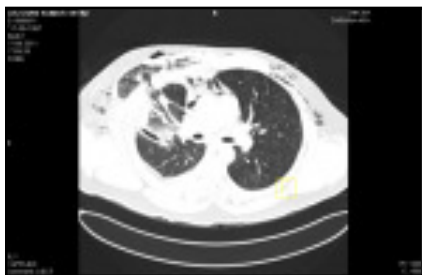


Fig 1. Contrast Enhanced Computerised Tomography Chest

Patient was planned for right postero-lateral thoracotomy. Operative findings were herniated right upper lobe through the fractured ribs anteriorly in the region of 4-6th intercostal space. Another incision was given over the right 5th intercostal space anteriorly over the herniated tissue (*Fig 2*) The herniated lung was reduced. (*Fig 3*) The defect was anteriorly repaired.

Postoperatively patient was kept on ventilatory support and thoracic epidural for pain relief was given. On the very next day patient was extubated with full consciousness level, gradually chest tube output decreased and drain was removed on day 4. The patient recovered fully and was discharged on day 7.

Discussion

Lung herniation is uncommon and has been defined as the protrusion of pulmonary tissue and pleural membranes through defects of the thoracic wall, (1) which may be congenital, spontaneous, or pathologic or may be the result of thoracic wall trauma (2). The majority of acquired pulmonary hernias are of traumatic origin (3,1,4). Hernias caused by blunt chest trauma more frequently arise anteriorly near the sternum or posteriorly, where there is only one intercostal muscle layer, and they usually protrude between rib spaces (5, 3,6,7). Intercostal lung hernias usually protrude through thoracic wall defects caused by costal or sternal fractures or associated rib-chondral separation (1,7,8). Supraclavicular pulmonary herniations occur as a result of clavicle-sternal dislocation (1,5). Most spontaneous lung hernias are associated with conditions of prolonged or excessive increase in intrathoracic pressure and have a predilection for areas of potential weakness in the chest wall (3,7). These areas

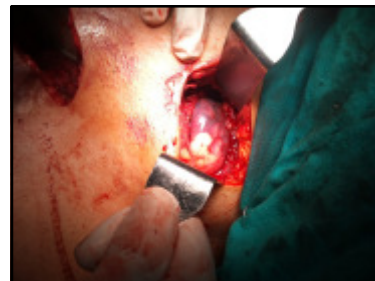

Fig 2. Operative Findings were Herniated Right Upper Lobe through the Fractured Ribs Anteriorly in the Region of 4-6th Intercostals Space

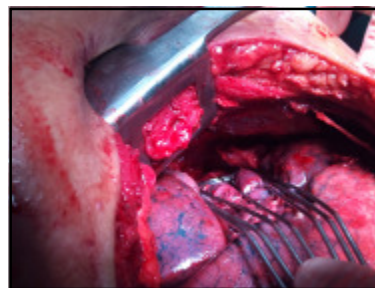

Fig 3. Showing Herniated Lung Being Reduced

occur anteriorly from the costochondral junction to the sternum because of the absence of external intercostal muscles (3,7,8) The anterior thorax is the site of predilection for both spontaneous and traumatic lung herniations, presumably because the anterior thorax lacks the muscular support afforded the posterior thoracic wall by the trapezius, latissimus dorsi, and rhomboid muscles (6,8). Most patients with lung hernias are asymptomatic. The usual sign is a bulging mass in the chest wall or neck associated with coughing, straining, or lifting. A soft, smooth, reducible mass that changes in size with respiration, protruding through a palpable defect in the chest wall, is usually evident on examination (3,7,8). Posttraumatic lung herniation can be visualized on chest radiographs as a well-circumscribed area of subcutaneous air, although tangential views may be necessary in some patients, such as the one in this report (2,7). CT provides valuable information regarding the thoracic wall and pleural space and better defines the dimensions of the hernia. The more liberal use of CT may expand the number of diagnoses. Early surgical repair offers the best



results with a low morbidity, and the long-term prognosis is excellent (2,9). The true incidence of traumatic lung herniation is difficult to assess because it is likely that many hernias remain occult because of a low index of suspicion, subtle physical findings, and lack of symptoms (10). Incarceration is unusual, but if it happens, it is usually because of an entrapment of the lung on rib spicules at the site of rib fractures (1). Lung herniations are unlikely to recover spontaneously. In the past, small hernias were managed by means of thoracic strapping. However, primary surgical repair is better, and strapping has been abandoned because it impairs thoracic wall motion, reduces pulmonary compliance, and increases the incidence of atelectasis and infection (9,11). Pericostal fixation of adjacent ribs with absorbable sutures is usually enough to bridge the defect. In addition, the ribs can be divided and released from their pericostal envelopes before being shifted into place. Larger defects may require fascia lata grafts and muscle flaps to close the defect, and when the thoracic wall defect is too large to allow direct sutures, a prosthetic patch may be used, as in the patient in this report (1,12). Seroma is a possible complication. Exceptionally, resection of the incarcerated lung may be necessary before closing the thoracic wall defect (10). Early surgical management is recommended for best results with a low morbidity and for excellent long-term prognosis (10).

References

1. Francois B, Desachy A, Cornu E, Ostyn E, Niquet L, Vignon P. Traumatic pulmonary hernia: surgical versus conservative management. *J Trauma* 1998;44:217-19.
2. Tack D, Wattiez A, Schtickzelle JC, Delcour C. Spontaneous lung herniation after a single cough. *Eur Radiol* 2000;10:500-02.
3. Fiane AE, Nordsrand K. Intercostal pulmonary hernia after blunt thoracic injury. *Eur J Surg* 1997;159:379-81.
4. Kyosola K, Reinikainen M, Siitonen P, Valli H. Lung hernia after blunt thoracic trauma. *Acta Chir Scand* 1984; 150:425-28.
5. Arajavi E, Santavirta S. Chest injuries sustained in severe traffic accidents by seatbelt wearers. *J Trauma* 1989; 29:37-41.
6. May AK, Chan B, Daniel TM, Young JS. Anterior lung herniation: another aspect of the seat belt Syndrome. *J Trauma* 1995;38:5887-89.
7. Saw EC, Yokoyama T, Lee BC, Sargent EN. Intercostal pulmonary hernia. *Arch Surg* 1976;111:548-51.
8. Soreide O, Stedjeberg JO. Traumatic intercostal pulmonary hernia. *Injury* 1975;7:61-62.
9. Scullion DA, Negus R, Al-Kutoubi A. Case report: extrathoracic herniation of the lung with a review of the literature. *Br J Radiol* 1994; 67:94-96.
10. Allen GS, Fischer RP. Traumatic lung herniation. *Ann Thorac Surg.* 1997; 63:1455-56.
11. Forty J, Wells C. Traumatic intercostal pulmonary hernia. *Ann Thorac Surg* 1990; 49:670-71.
12. Cernilia J, Lin J, Ott R, Scannell G, Waxman K. A technique for repair of traumatic parasternal lung herniation: case report. *J Trauma* 1995; 38:935-36.