

A Giant Inguinoscrotal Hernia

Vikas Gupta, Ashwani K Sharma, R K Chrungoo

Abstract

We report a case of giant inguinoscrotal hernia. Such hernial formations are rare (5% cases) and largely a problem of developing countries. Problems arise in the management for both the patient and the surgeon because of the rarity of the reported cases as there is no standard surgical procedure in place for their treatment. Surgical management of such giant hernias has to be individualised.

Key Words

Hernia, giant inguinoscrotal hernia, pneumoperitoneum, intestinal obstruction

Introduction

Giant inguinal hernias present formidable surgical problems. Morbidity and mortality associated with their repairs are high (1). Though, hernias of this magnitude are rare, their management can be demanding and challenging. We present a case of a long standing giant inguinoscrotal hernia complicated by intestinal obstruction

Case Report

A 58 year old male presented with a clinical picture of obstructed right inguinal hernia. Routine examination revealed a large scrotal swelling extending up to the knees, developed over a period of 8 years progressively.

On abdominal examination patient had mild distension and bilateral lower abdominal tenderness. Examination of the groin revealed a large bilateral inguinoscrotal swelling which was tender on palpation and was irreducible. There was no cough impulse present at the hernial orifices. The scrotal skin was thickened. (Fig. 1, Fig. 2). An ultrasound scan of the scrotum reported dilated gut loops in the scrotum suggestive of an enterocoele.

Patient was operated as an emergency case and no attempt was made to apply pre-operative pneumoperitoneum to increase intra-abdominal capacity. Right inguinal incision was made and extended over right scrotum. Hernial sac was opened. Hernial contents included terminal ileum, appendix, caecum and ascending colon (Fig. 3).

Internal ring was enlarged. Reduction of contents was not possible. Part of gut in the hernial sac was found to be healthy. Lower midline incision was made and laparotomy done. Contents of the hernial sac were reduced after enlarging hernial orifice. Right orchidectomy was done. Two layered double breasted nylon repair of inguinal canal was done (Fig. 4). Redundant scrotal skin was excised and scrotal reconstruction done (Fig. 5). Abdominal wound was closed with mass closure technique. Post-operative recovery of the patient was uneventful and he was discharged on 8th post-operative day. Six months after the operation no evidence of recurrence or lymphoedema was found.

From the Post Graduate Deptt. of Surgery, Govt. Medical College, Jammu (J&K).

Correspondence to : Dr. Vikas Gupta, Registrar, PG Department of Surgery, Govt. Medical College, Jammu.

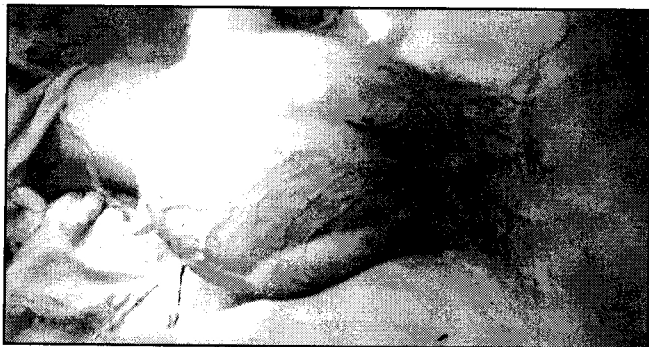

Fig.1 Showing giant right inguino-scrotal hernia.

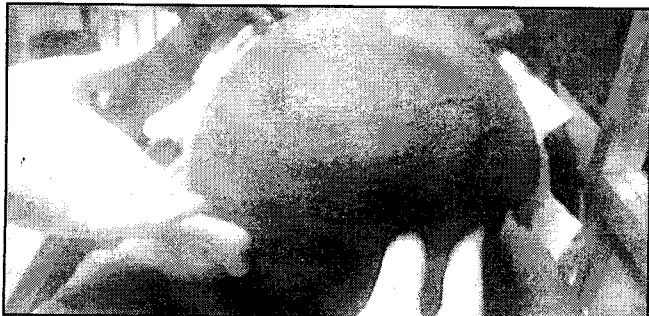

Fig. 2 Showing giant right inguino-scrotal hernia.

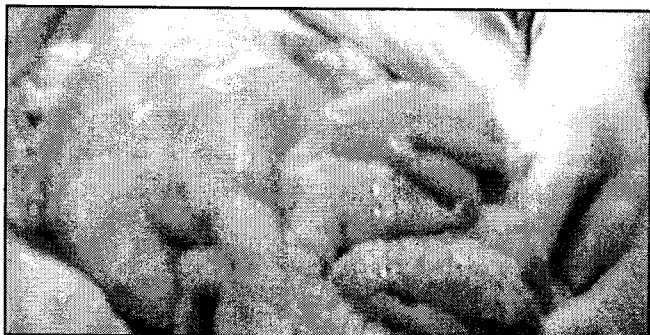

Fig. 3 Showing hernial contents including terminal ileum, appendix, caecum and ascending colon.

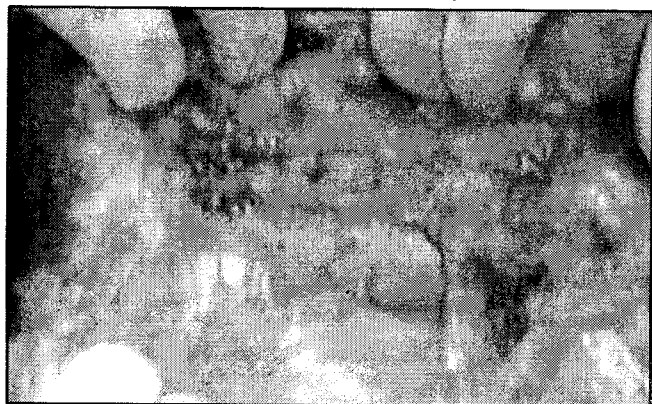


Fig. 4 Showing two layered double breasted nylon repair of inguinal canal.

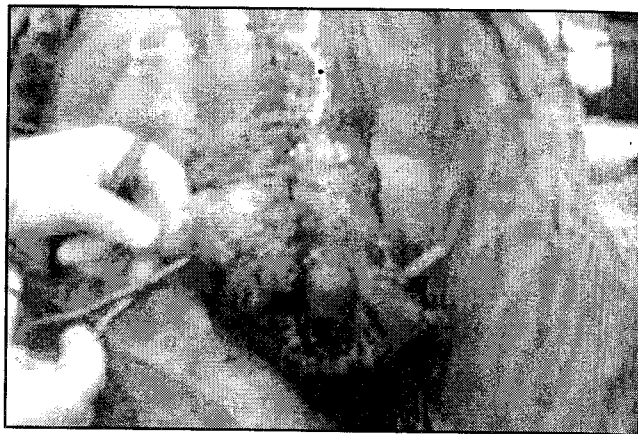


Fig. 5 Showing completed hernial repair and scrotal reconstruction.

Discussion

Giant inguinoscrotal hernias are uncommon and present a major challenge in management. They are defined as hernias that extend below the midpoint of inner thigh in standing position (1). Patients usually encounter difficulty in walking, sitting or simply lying down and their mobility is drastically restricted. Varied clinical presentations seen in such patients include acute retention of urine, gangrene and ulceration of scrotal skin and bowel obstruction.

Problems arise in management for both the patient and the surgeon because of rarity of the reported cases as there is no standard surgical procedure in place for their management. Few surgical techniques have been described in the literature for repairing giant inguinoscrotal hernias. Frequent insufflations of air into the abdominal cavity in order to create space to accommodate herniated viscera and facilitate fascia repair with minimal tension has been commonly employed (2). The patient is ready for his operation approximately two weeks after creating pneumoperitoneum and may experience discomfort, shoulder pain, dyspnoea and tachycardia.

Bowel resection in the hernial sac in order to debulk the contents of the hernial sac and abdominal wall reconstruction using marlex mesh and a tensor fasciae lata flap has also been described (3). Merett *et al.* described a technique for the repair of giant inguinoscrotal hernia. It consists of reduction of the hernia, repair of the hernial orifices with marlex, creation

of a midline anterior wall defect to increase intra-abdominal capacity, covering this defect with marlex mesh, then covering the midline marlex mesh with a rotation flap of inguinoscrotal skin (4). This technique increases the intra-abdominal capacity and allows reduction of hernia and includes two separate procedures with no attempt of reperitonealisation underneath the prosthetic mesh.

El-Dessouki described a technique in 2001 to create a midline abdominal wall defect to increase the intra-abdominal capacity to accommodate the hernial contents (5). The hernial sac is then pulled up to the abdomen and fashioned as a rotation flap to augment and close the peritoneum over the replaced contents. Lastly a giant polypropylene mesh is inserted in the preperitoneal space to cover the created midline defect and buttress both inguinal regions. Zuvella M *et al.* described the Rives technique (direct inguinal approach) in the treatment of large inguinoscrotal and recurrent hernias (6). Positioning of the mesh with non tensional techniques can be completed on different levels, with big hernias where the biggest part of transversalis fascia of myopectineal orifice is destroyed it is anatomically the most useful to place the mesh in the preperitoneal space. Rives technique is the base of that concept and it presents one of the good solutions in that kind of situations. In view of the above mentioned surgical options, the management

of giant inguinal hernias has to be adapted to the individual situation of the patient.

Our patient was operated as an emergency case and thus no attempt to apply pre-operative pneumoperitoneum was made. Inguinal incision was accompanied by a midline lower abdominal incision to facilitate reduction of hernial contents. Right orchidectomy, two layered double breasted nylon repair of inguinal canal and scrotal reconstruction was done. Post-operative course of the patient was uneventful.

References

1. Sarakbi W Al, Agrawal A, Taffinder N. A giant inguinoscrotal hernia: a case report and review of the literature. *Grand Rounds* 2005;5:46-48.
2. Willis S, Conze J, Muller S *et al.* Progressive pneumoperitoneum in treatment of inguinal and scar herniae. Results of animal experiments and clinical applications. *Langenbecks Arch Chir* 1996;381:132-7.
3. Mehendal FV, Taams KO, Kingsnorth AN. Repair of a giant inguinoscrotal hernia. *Br J Plast Surg.* 2000;53: 525-9.
4. Merett ND, Waterworth MW, Green MF. Repair of giant inguinoscrotal inguinal hernia using marlex mesh and scrotal skin flaps. *Aust N Z Surg* 1994;64:380-3.
5. El-Dessouki NI. Preperitoneal mesh hernioplasty in giant inguinoscrotal hernias: a new technique with dual benefit in repair and abdominal rooming. *Hernia* 2001;5:177-81.
6. Zuvella M, Milicevic M, Lekic N *et al.* The Rives technique (direct inguinal approach) in treatment of large inguino-scrotal and recurrent hernias. *Acta Chir Iugosl* 2003;50:37-48.

GUIDELINES FOR ARTICLES TO BE SUBMITTED UNDER EACH CATEGORY TO "JK SCIENCE" JOURNAL OF MEDICAL EDUCATION & RESEARCH

Article Type	Summary: No. of Words	Key Words: No. of Words	Text : No. of Words	Sub-Headings	Tables: Max. No.	Figures: Max. No.	No. of References
ED	NR	NR	600-800	NR	NR	NR	< 10
RA	NR	NR	3000	Variable	2	2	30-35
OA	200	3-5	2000	Standard	4	2	20-25
SC	100	3-5	1200	Standard	2	1	10-15
CR	< 50	3-5	600-800	Standard	1	3	< 10
DR	NR	NR	1000	NR	1	1	< 10

ED = Editorial RA = Review Article; OA = Original Article; SC = Short Research Communication; CR = Case Report; DR = Drug Review; NR = Not Required