



# Histopathology of Gastric Cancer in Kashmir – A Five Year Retrospective Analysis

Nassima Chanda, A. R. Khan\*, M. Romana, Saud Lateef\*\*

## Abstract

Our study was a five year analysis of gastric cancers performed in the Department of Pathology, Government Medical College, Srinagar. This included an analysis of 152 cases of gastric cancers which accounted for 21.9% of gastrointestinal cancers. Pylorus was the commonest site involved, followed by the body and then cardia-fundus. Grossly the commonest type was an infiltrative lesion. Microscopically according to Lauren's classification, intestinal type was the commonest (28%), followed by diffuse (27.3%) and mixed (8%). Chronic follicular gastritis, intestinal metaplasia and lymphoid hyperplasia were common findings in the intestinal type of adenocarcinoma.

## Key words

Gastric cancer, Pathology of cancer, Histological pattern

## Introduction

Gastric cancer is still one of the major causes of cancer deaths (1), although mortality has been consistently decreasing (2). At present it is the second most cancer after lung malignancy (2). Among the malignant tumours of the stomach, carcinoma is the commonest accounting for about 90-95% cases (3). Next in order of frequency being lymphomas (4%), carcinoids (3%) and malignant spindle cell tumours (2%) (4). The incidence is particularly high in Japan in comparison with Western countries (5). However, the decrease in incidence has not altered five year survival rates over the past 30 years speaking of poor prognosis of advanced gastric cancer. The incidence and mortality is double for males in both high and low risk countries (6). Environment plays an important role and common characteristics of high risk areas being high intake of starchy foods smoked and salted meat with low intake of fresh fruits and vegetables (7-10). Risk factors include atrophic gastritis with intestinal metaplasia (8-9), pernicious anaemia, adenomatous polyps (3) and previous partial gastrectomy.

This study in view of the high incidence of gastric cancer in Kashmir (9-11), is aimed at pathological analysis

of malignant gastric tumours from a five years retrospective study material (1989-1993) of gastrectomy specimens from Government Medical College. In view of the fact that a hospital based or a population based cancer registry is not available in the State of Jammu and Kashmir, this study may be of utility to understand the clinico-pathological characteristic of gastric cancer in a population which has a distinct social, cultural and geographic background.

A 15 year analysis of tumours of stomach and oesophagus carried out at Government Medical College, Srinagar, from 1984-1998 revealed that gastrointestinal malignancies accounted for 44% of total malignancies (12), out of which cancers of stomach and oesophagus comprised more than 75%.

## Material and Methods

The data for the study was collected from the records of Pathology Department of Government Medical College, Srinagar during the period of 1989-1993. The relevant clinical data was recorded from the case sheets of the patients. The total number of endoscopic biopsies and gastrectomy specimens were recorded. However, only gastrectomy specimens were analyzed in the study.

From the Deptts. of Pathology, SKIMS, Soura, Srinagar, \*Pathology & \*\*Surgery, GMC, Srinagar (J&K), India.

Correspondence to : Dr. Nassima Chanda, Assistant Professor, Department of Pathology, SKIMS, Soura, Srinagar (J&K), India.

The gross detail included topography and gross details of the tumour. Gross morphology was based on Borrmann (1926) classification as; polypoid, fungating, infiltrating and ulcerative types. Microscopic data was recorded from the available sections and recent blocks, using haematoxylin and eosin, routinely. Special stains like PAS and Alcian blue and reticulin were used wherever indicated. The histological classification was based on Laurens (1965) classification as follows : (1) Intestinal type, (2) Diffuse type and (3) Mixed type.

### Results

In the study of gastric cancer of Kashmir , one hundred and fifty two histologically confirmed specimens resected surgically were analyzed. Table-1 provides an overview of the high percentage of gastric cancers which comprise more than 21% of the total GIT malignancies in the 5 year interval studied. Males outnumbered females in the ratio 3:1. The males were mostly affected in the 5th decade and females in the 4th decade of their life.

It was observed that pyloric antrum was the commonest site involved followed by body and then cardia-fundus in both the sexes. Pyloric antrum was also the commonest site for all 4 gross morphological types of tumours. Out of these, 150 cases were adenocarcinomas and their variants (2 adenocarcinoma – carcinoid, 1 adenocarcinoma with squamous cell carcinoma). There were 2 cases of Non-Hodgkin’s lymphoma also.

Histologically intestinal type of carcinoma was seen in 28%, diffuse in 27.3% and mixed in 8% cases. One case of adenosquamous (0.6%) and two cases of adenocarcinoma-carcinoid (1.3%) were located at the pyloric antrum. The diffuse type occurred mostly at the body of the stomach.

Males were predominantly affected by intestinal type (35.1%) of gastric carcinoma, followed by diffuse type (30.4%) whereas the reverse was seen in females. The mixed type affected mostly the males in our observation. Early gastric cancer was seen in 2 cases in the 4th and 5th decade of their life in both male patients. The lesion was an ulcerative type at the pyloric antrum. In one of the patients, intestinal metaplasia and in the other chronic gastritis were additional findings.

Other characteristics noted in our study included an associated factor analysis i.e. intestinal metaplasia, chronic follicular gastritis and lymphoid hyperplasia (Table-3). Intestinal metaplasia, chronic follicular gastritis and lymphoid hyperplasia were more common in intestinal type of gastric carcinoma.

**Table 1: Analysis of stomach cancers**

Year	A	B	C	D
1989	180	25	07	18
1990	102	15	04	11
1991	167	36	15	21
1992	97	28	07	31
1993	148	28	06	32
<b>5 years</b>	<b>694</b> (46.5%)	<b>152</b> (21.9%)	<b>39</b> (25.65)	<b>113</b> (74.3%)

A = Total No. of GIT malignancy Endoscopic biopsy/ specimen, B = Total No. of stomach specimens, C = Total No. of malignancies in females, D = Total No. of malignancy in males

**Table 2. Relation of site with sex**

<b>Pyloric antrum</b>	<b>98 (65.3%)</b>		
Male	78	Female	21
<b>Body</b>	<b>41 (27.3%)</b>		
Male	25	Female	16
<b>Cardia fundus</b>	<b>11 (7.3%)</b>		
Male	9	Female	2

**Table 3: Prevalence of intestinal metaplasia, chronic follicular, gastritis and lymphoid hyperplasia in various histological types.**

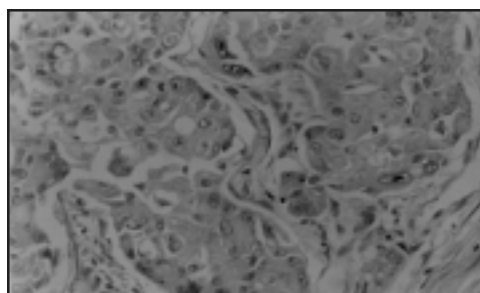
Histological type	IM N (%)	CFG N (%)	LH N (%)
Intestinal type	14 (9.3)	9 (6)	9 (6)
Diffuse type	7 (4.6)	5 (3.3)	6 (4)
Mixed type	1 (0.6)	1 (0.6)	2 (1.3)

IM = Intestinal Metaplasia, CFG = Chronic follicular Gastritis, LH = Lymphoid Hyperplasia.

**Table-4: Shows gastric carcinoma histology utilizing Lauren’s classification.**

S.No.	Form/Type Microscopic	P	B	C&F
1	Intestina	42 (28%)	12 (8%)	8 (5.3%)
2	Diffuse	41 (27.3%)	23 (15.3%)	3 (2%)
3	Mixed	12 (8%)	6 (4%)	-
4	Adenosquamous carcinoma	1 (0.6%)	-	-
5	Adenocarcinoma with carcinoid	2 (1.3%)	-	-
<b>Total 150 Cases</b>		<b>98 (65.3%)</b>	<b>41(27.3%)</b>	<b>11 (7.3%)</b>

P = Pyloric antrum, B = Body of stomach, C&F = Cardia & fundas



**Fig.1: Well-differentiated adenocarcinoma H&E X 400**

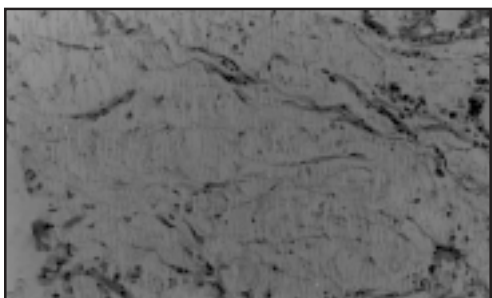


Fig.2: Mucinous Carcinoma H&E X 400

## Discussion

Kashmir has an unprecedented high incidence of gastric cancer possibly due to their special personal habits like smoking of *Hukka* and consuming dried and pickled vegetables, smoked fish and mixed spice/cake (*Wur*) (10,11).

In our study of 1490 cases of malignancies over a period of 5 years, 694 cases were G.I.T malignancies (including endoscopic biopsies) which comprised 46.5% of total malignancies. It included 152 cases (21.9%) of gastrectomy specimens. The incidence here is higher as compared to other parts of India where it is less. In Kerala it is 15.9% (13).

The majority of our patients were males in the 5th decade of their life and the youngest was 20 year old. Male:female ratio was 3:1 which was in accordance with other studies i.e. Paymaster *et al* (14).

The pyloric antrum was the commonest site (65.3%) for gastric carcinomas, followed by body (27.3%) and cardia-funds (7.3%). Our findings were in conformity with those of Ming (15), Gangadharana Reddy (16). Commonest site was pyloric antrum in 50.6% males and in 14.6% females. This differed from Donald and Goldman (17) who found that cardia was mainly affected in both sexes.

In advanced gastric carcinomas, infiltrative type of tumour was the commonest (68.9%), out of which 65.5% were localized type and 3.3% were diffuse (*Linitis plastica*) type. The other types in decreasing order were ulcerative (18.9%), fungating (6.7%) and polypoid (5.4%). Our findings did not match with those of Cassell and Robinson (18), who found that ulcerative type occurred in 51% and infiltrative in 32% and polypoid in 17% of cases. However, the findings matched with those of Schindler *et al* (19) who also found infiltrative lesion to be commonest (63.2%), followed by ulcerative (17.6%), fungating (16.3%) and polypoid (2.9%).

In our study using Lauren's (20) classification, intestinal type of carcinoma predominated at the pyloric antrum (28%) followed by body (8%) and cardia-fundus (5.3%).

Diffuse type was involving the pyloric antrum (27.3%), body (15.3%) and cardia-fundus (2%) (Table-4). The mixed type was also seen mostly at the pyloric antrum (8%) and body (4%). Our findings correspond with those of Ming (15) who also found that intestinal type of lesion was commonest in the pyloric region (59%), fundus (28%), both regions (12%) and whole body (1%).

We had one case of adenosquamous carcinoma with a fungating growth at the pyloric antrum with microscopic infiltration limited to serosa and no lymph node metastasis. This was in accordance with O'Brien (21), Lester (22) and Cruze *et al* (23).

Two cases of adenocarcinoma with carcinoid at the pyloric antrum along the lesser curve were seen by us. The lesion was ulcerative type with diffuse (signet ring morphology) adenocarcinoma and carcinoid in first part of duodenum. Both patients had lymph node metastasis of adenocarcinoma. Yamashina and Flinner (24) found a polypoid tumour in the mid greater curvature of the stomach with same microscopic findings as ours. Well differentiated tubulo papillary adenocarcinoma and a carcinoid at the pyloric antrum with lymph node metastasis of adenocarcinoma was reported by Jayaraman *et al* (6).

Early gastric carcinoma was seen in two cases (1.3%). Both were males in the age group of 40-50 years. Both were intramucosal (intestinal type). One case had associated chronic gastritis and the other had intestinal metaplasia. Our findings correlated with Ivans *et al* (25), who had 1.9% cases with same associated findings.

Two cases of Non-Hodgkin's lymphoma were also seen in our study. Both were females in the age group of 35-45 years. Macroscopically pyloric antrum was involved by an infiltrative type of lesion in one case with microscopic picture of follicular mixed cell. The other case had an ulcerative lesion which was microscopically large cell (follicular cell) type. Our findings were similar to those of Dragosics *et al* (26). Stomach is a frequent site for GIT lymphomas (27) comprising about 69% of total lymphomas with a male preponderance and median age of 52 years.

Our study of analysis of gastric cancers throws a light on the pattern of gastric cancer seen in Kashmir Valley. Although it is a retrospective analysis yet several features like sub-site, histological type and presence of various associated factors like chronic follicular gastritis and intestinal metaplasia were seen in a sizeable percentage of our patients (14.47%) and (10%) respectively. They are pointers towards an aetiological factor which needs to be worked out in order to find an association. Due to lack of clinical output the other risk factors like food etc.



could not be evaluated to study a cause effect relationship. However, prospective analysis and experimental studies are warranted to find out the same. The pattern of cancer in Kashmir especially the cancer of GIT is changing, as more complex environmental and other factors are coming into play. A fifteen year analysis of gastric and oesophageal cancers carried out at Government Medical College, Srinagar, revealed an emerging high percentage of patients with cancers at oesophago-gastric junction possibly because of an increased incidence of adenocarcinomas at this site than reported previously (12).

#### References

1. Pisani P, Parkin DM, Ferlay J. Estimates of the worldwide mortality from twenty-five major cancers in 1990. *Int J Cancer* 1999; 83: 18-29.
2. Tominaga S, Kurioki T, Aoki K. Cancer mortality statistics in 33 countries 1953-1992. UICC, Nagoya: Roppo Shuppaco Ltd., 1998.
3. Si-Chun M, Harvey G. Gastric polyps. A histogenetic classification and its relation to carcinoma. *Cancer* 1965; 18(6): 721-26.
4. Kumar, Cotran and Robbins. Pathological Basis of Disease. Published by Prism Books Pvt. Ltd., 1994, 5th edition, pp. 779.
5. The EUROGAST study group. An international association between Helicobacter pyloric infection and gastric cancer. *Lancet* 1993; 341: 1359-62.
6. Jayaraman A, Ramesh S, Jeyasingh R, Karur RB. Gastric collision tumour – a case report. *Ind J Pathol Microbiol* 2005; 48(2): 264-65.
7. Azra S. Pattern of gastrointestinal tumour in Kashmir. *JK Practitioner* 1995; 2(3): 109-11.
8. Morson BC. Intestinal metaplasia of gastric mucosa. *Brit J Cancer* 1995; 9: 365-77.
9. Sipponen P, Kekki M, Siurala Max. Atrophic chronic gastritis and intestinal metaplasia in gastric carcinoma. *Cancer* 1983; 52: 1062-68.
10. Diwani HA, Malik GM, Tikku NM, Khan M. The presentation of gastric cancer in Kashmiri native and analysis of 850 cases. *JIMA* 1988; 20: 50-53.
11. Khuroo MS, Zargar SA, Mahajan R, Banday MA. High incidence of oesophageal and gastric cancer in Kashmir in a population with special personal and dietary habits. *Gut* 1992; 33: 11-15.
12. Rumana Makhdoomi, Khan AR, Khursheed N, Seema Ali, Besina S, Loan NA. The changing pattern of oesophagus gastric cancer in Kashmir. *JK Practitioner* 2005; 12(4): 189-92.
13. Jose L, Nalappat S, Sisidharan VP. Department of Pathology, Medical College Calicut, Kerala. A clinico-pathological study of carcinoma stomach. *Ind J Pathol Microbiol* 1995; 38: 73-79.
14. Paymaster JC, Sanghvi, Gangadharan P. Epidemiological study. *Cancer* 1968; 21: 278-88.
15. Si-Chun M. Gastric carcinoma. *Cancer* 1977; 39: 2475-85.
16. Gangadharan D, Reddy DB. Carcinoma of the stomach. *Ind J Path Bact* 1962; 5: 80-92.
17. Donald A, Antonioli, Goldman H. Changes in the location and type of gastric adenocarcinoma. *Cancer* 1982; 50: 775-81.
18. Cassell P, Robinson JO. Cancer of the stomach : a review of 854 patients. *Br J Surg* 1976; 63: 603-07.
19. Schindler R, Steiner PE, Smith WM, Dailey ME. The classification of gastric carcinoma. *Surg Gynaecol Obst* 1941; 73: 30-39.
20. Pekka Lauren. The two histological main types of gastric carcinoma : Diffuse and so called intestinal type carcinoma. *Acta Path Microbiol Scand* 1965; 64: 31-49.
21. Joseph PO', Brien MD, Meehan DJ, Buffalo NY. Adenoacanthoma of the pyloric end of the stomach. *Surg* 1950; 28: 1005-08.
22. Nagel LR. Adenoacanthoma of the stomach. *Archives Pathol* 1956; 62: 37-40.
23. Cruze K, Mass HE, Clarke JS, Mass HE, Clarke JS, Sabriel Farra BA. Squamous cell carcinoma of the stomach : a case report. *Gastroenterol* 1960; 39: 787-89.
24. Yamashina M, Flinner RA. Concurrent occurrence of adenocarcinoma and carcinoid tumour in the stomach : A composite tumour or collision tumours. *J Clin Pathol* 1985; 83: 233-36.
25. Ivans DMD, Craven JL, Murphy F, Cleary BK. Comparison of early gastric cancer in Britain and Japan. *Gut* 1978; 19: 1-9.
26. Dragosics B, Bauer P, Radaszkeiwicz T. Primary gastrointestinal Non-Hodgkin's lymphoma. *Cancer* 1985; 55: 1060-73.
27. Eser B, Kaplan B, Unal A, Canoz O *et al*. Clinicopathologic characteristics and therapeutic outcomes of primary GIT Non-Hodgkin's lymphomas in Central Anatolia, in Turkey. *Yonsei Med J* 2006; 47(1): 22-33.