

# Giant Aneurysm of the Internal Carotid Artery

Archana Ahluwalia, Seerat Sandhu, Rajinder Pal Singh Bajwa

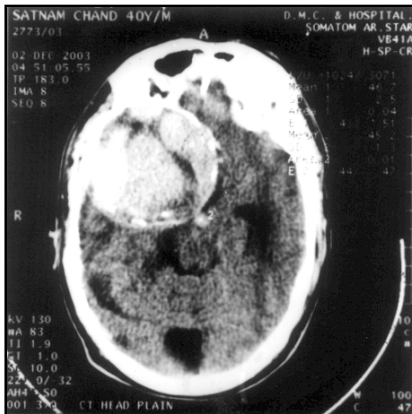

Fig. 1. Giant Aneurysm of the internal carotid artery. (Plain CT scan)

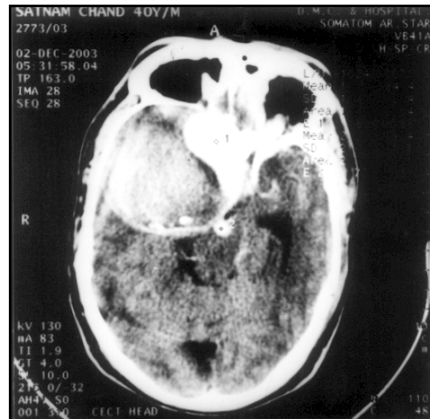


Fig. 2. Giant Aneurysm of the internal carotid artery (CECT).

## Case

A 40 year male presented with sudden loss of consciousness. There was history of progressive loss of vision in the right eye and dull pain in the right temporal region. He was subjected to a CT scan of the head. Plain CT scan (Fig. 1) shows a 6.8x6.6x6.0 cm heterogenous SOL with a well defined calcified rim and irregular hypodense areas in the right fronto-temporoparietal region causing mass effect on the ipsilateral basal cisterns. CECT at the same level (Fig. 2) shows an area of peripheral enhancement which is almost parallel to that of vessels-suggesting the diagnosis of a partially thrombosed giant aneurysm arising from the internal carotid artery.

## Discussion

A diagnosis of a partially thrombosed giant aneurysm arising from the right internal carotid artery was made on imaging. Cerebral aneurysms are found in approximately 0.5-5% of the population. Giant aneurysms (larger than 2.5cm) represent only 5-7% of these. Giant sacs commonly contain multilayered laminated clots of varying ages and consistency. Slow growth can occur by recurrent haemorrhages into the lesion. The highly vascularised membranous wall of giant aneurysms is the most likely source of these haemorrhages. Since the outer wall is fibrous and thick, these multilaminated aneurysms seldom rupture into the subarachnoid space and typically produce symptoms related to their mass effect. Although the treatment of choice for cerebral aneurysms is surgical, inoperable symptomatic giant aneurysms can be successfully treated with endovascular alternatives. These consist of occlusion of the carrier vessel with endovascular balloons after previous test occlusion. Endovascular coil embolisation maybe useful in the treatment of cases not amenable to balloon embolisation.

From the Department of Radiodiagnosis, Dayanand Medical College & Hospital, Ludhiana (Punjab).

Correspondence to : Dr. Archana Ahluwalia, 125-D, Kitchlu Nagar, Ludhiana-141001, Punjab.