

**CASE REPORT**

## Intrahepatic Portal Vein Aneurysm: Incidental Ultrasound Diagnosis of an Uncommon Entity

Chandrashekhar Sohoni

**Abstract**

Portal vein aneurysm is a relatively uncommon entity. It is often an incidental, asymptomatic finding. This pathology is increasingly encountered with frequent use of radiological imaging modalities. We report a case of intrahepatic portal vein aneurysm diagnosed incidentally on ultrasonography in a case of acute gastritis. Recognition of this finding can help to avoid confusion with abdominal masses of other etiologies.

**Key Words**

Portal Vein, Aneurysm, Colour Doppler

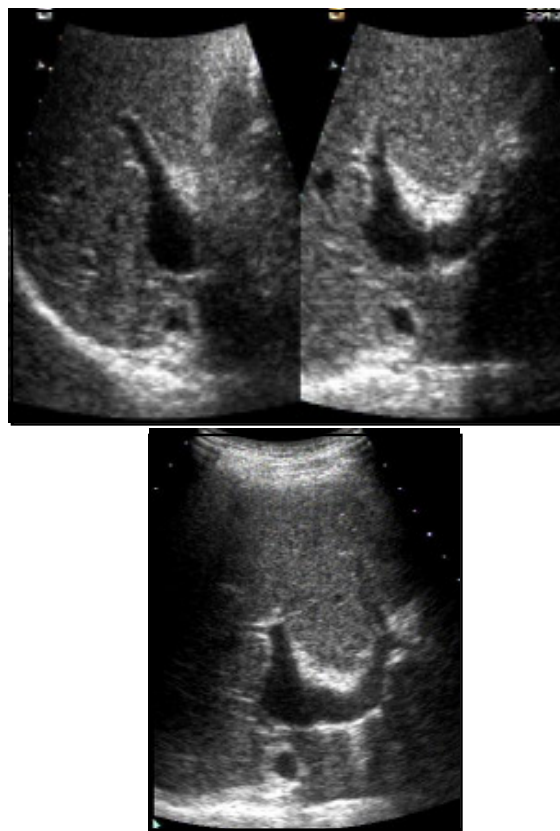**Introduction**

Being a rare clinical entity, not many cases of portal vein aneurysm have been reported in medical literature (1). Portal vein aneurysms are defined as focal dilatation of portal venous system, either extrahepatic or intrahepatic. Ultrasonography with colour doppler imaging is a reliable modality to make the diagnosis (2,3).

**Case Report**

A 65 year old diabetic, hypertensive male patient presented with severe pain in epigastrium associated with nausea and non-bilious vomiting since two days. Physical examination was unremarkable. His blood investigations revealed a normal haemogram, renal and liver function tests. Serum electrolytes and amylase and lipase levels were within normal limits. Ultrasonography of abdomen revealed a 2.4 x 2.0 cm anechoic mass in the right lobe of liver contiguous with the junction point of main portal vein and it's right division. On colour doppler imaging, continuous monophasic flow pattern was seen within the mass suggesting the diagnosis of intrahepatic portal vein aneurysm. The ultrasonographic study was otherwise unremarkable. Upper gastrointestinal endoscopy revealed inflammation of gastric mucosa. The patient was successfully treated for acute gastritis and discharged on the fourth day of admission.

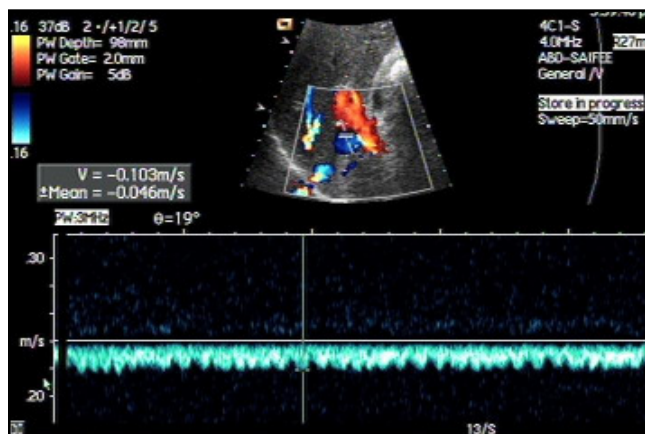
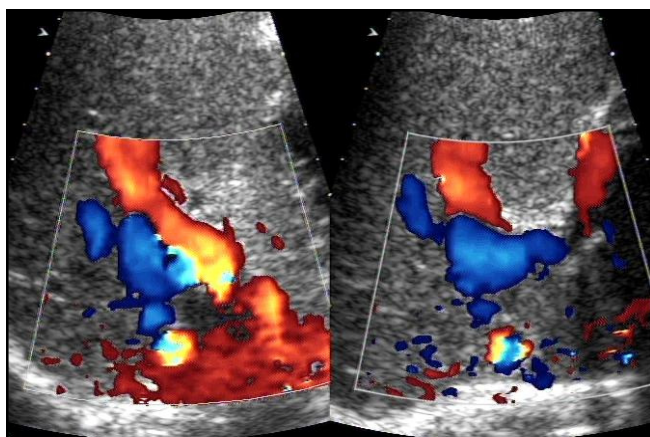
*Fig. 1 & 2 The B- mode Images Reveal Focal Dilatation of Intrahepatic Portal Vein*



**From the Deptt. of Imaging Saifee Hospital, Maharshi Karve Marg, Mumbai - India**

**Correspondence to :** Dr. Chandrashekhar Sohoni, Consultant Radiologist, Dept. of Imaging Saifee Hospital, Maharshi Karve Marg, Mumbai

**Fig. 3& 4. The Colour Doppler Images and Spectral Trace Demonstrate Continuous, Monophasic Flow Characteristic of Portal Circulation**



### Discussion

Although uncommon, an aneurysm of the portal venous system is the most common site of visceral venous aneurysms. They can occur in the intrahepatic or extrahepatic segment of portal vein, extrahepatic being more common. Though exact mechanism is unknown, various etiologies ranging from congenitally defective regression of right primitive vitelline vein to acquired causes such as portal hypertension, liver cirrhosis, trauma, pancreatitis, liver biopsy or tumor invasion have been reported (3-6). In our case, a diagnosis of congenital origin can be suggested because no other cause was found. Maximum extrahepatic portal vein diameter has been reported  $\leq 1.5$  cm in normal individuals and  $\leq 1.9$  cm in cirrhotic patients, with values of  $>2.0$  cm considered aneurysmal (2,8). The cut-off value for diagnosing intrahepatic portal vein aneurysm is less universally agreed upon, although some authors consider a diameter of intrahepatic portal vein  $>0.7$  cm in normal individuals and  $>0.8$  cm in cirrhotic patients as aneurysmal(8). Ultrasonography with colour doppler which displays the typical spectral pattern, is a reliable modality for diagnosis of this condition (2,3). Colour doppler imaging helps differentiate this condition from other lesions such as a simple hepatic cyst or cystic metastasis. In conclusion, ultrasonography with colour doppler imaging is reliable to make an accurate diagnosis in uncomplicated cases of intrahepatic portal vein aneurysm.

### Conclusion

Portal vein aneurysm is a relatively uncommon entity. It is often an incidental, asymptomatic finding. Early recognition of this finding can help to avoid confusion with abdominal masses of other etiologies.

### References

- 1) Ohnami Y, Ishida H, Konno K, *et al.* Portal vein aneurysm: report of six cases and review of the literature. *Abdom Imaging* 1997; 22:281-86.
- 2) Lopez-Machado E, Mallorquin-Jimenez F, Medina-Benitez A, Ruiz Carazo E, Cubero GM. Aneurysms of the portal venous system: ultrasonography and CT findings. *Eur J Radiol* 1998;26:210-14.
- 3) Ozbek SS, Killi MR, Pourbagher MA. Portal venous system aneurysms: report of five cases. *J Ultrasound Med* 1999;18:417-22.
- 4) Ryan B, Schwoppe, Daniel J. Margolis, Steven S. Raman, Barbara M. Kadell. Portal Vein Aneurysms: A Case Series with Literature Review. *Radiology Case* 2010 ;4(6):28-38.
- 5) Gallagher DM, Leiman S, Hux CH. In utero diagnosis of a portal vein aneurysm. *J Ultrasound Med* 1993;21:147-51.
- 6) Yang DM, Yoon MH, Kim HS, Jin W, Hwang HY, Kim HS. CT findings of portal vein aneurysm caused by gastric adenocarcinoma invading the portal vein. *Br J Radiol* 2001 ;74(883):654-56
- 7) Doust B, Pearce J. Grey scale ultrasonic properties of normal and inflamed pancreas. *Radiology* 1976;20:653-57.