

“Hair on End” Skull Induced by Renal Cell Carcinoma

Paramdeep Singh, Kavita Sagar, Vishal Kalia, Munish Guleria

A 47-year-old female had an incidental finding of left renal SOL when patient approached for regular check up. She was operated and was found to have renal mass adherent to Pancreas and descending colon. Histopathology revealed Clear cell renal cell carcinoma. Patient subsequently presented with swelling in frontal head region. Complete hemogram and other routine biochemical tests were done and were normal. X ray skull was done and revealed "Hair on end" periosteal reaction in frontal head region (Fig. 1 & 2).

Periosteal new bone/periosteal reaction is an important radiological feature seen in many abnormalities, especially tumour and infection. Hair on end appearance is produced by spiculated continuous periosteal reaction. These spicules are composed of normal reactive bone. Loose areolar tissue between spicules is replaced by tumour tissue in malignant lesions or by hyperplastic red marrow in hemolytic anemias (1).

Differential diagnosis of this type of periosteal reaction include hemolytic anemias, Osteosarcoma, Ewing's sarcoma, metastasis (malignant Neuroblastoma, Renal cell carcinoma) and Hemangioma (1,2). These changes can also be rarely seen in patients with severe iron deficiency anemia (3) and cyanotic congenital heart disease (4). It has also been described in a patient with severe congenital neutropenia after a long term G-CSF treatment (5).

Therefore cases having hair on end skull, radiological findings should be correlated with history/clinical findings and relevant investigations to know the exact etiology.

References

1. Berry M, Chowdhury V, Mukhopadhyay S, Suri S, Pawa S, editors. 2nd edition. Diagnostic radiology: Musculoskeletal and breast imaging. New Delhi: Jaypee brothers; 2005.pp. 10-11
2. Yochum TR, Rowe L.J. 3rd edition. Essentials of skeletal radiology. Philadelphia: Lippincott Williams and Wilkins;1996. Vol 2 pp. 1204
3. Britton HA, Canby JP, Kohler CM. Iron deficiency anemia producing evidence of marrow hyperplasia in the calvarium. *Pediatrics* 1960;25:621-28
4. Walor DM, Berdon WE, Westra SJ. "Hair-on-end" skull changes resembling thalassemia caused by marrow expansion in uncorrected complex cyanotic heart disease. *Pediatr Radiol* 2005; 35:698-701
5. Albert MH, Notheis G, Wintergerst U, Born C, Schneider K. "Hair-on-end" skull induced by long-term G-CSF treatment in severe congenital neutropenia. *Pediatr Radiol* 2005 ; 37(2):221-24

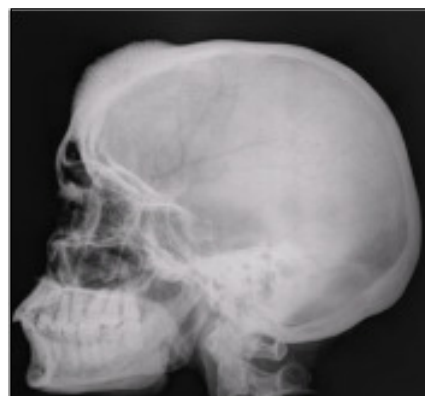

Fig 1. X ray Skull Lateral View showing "Hair on End" Appearance

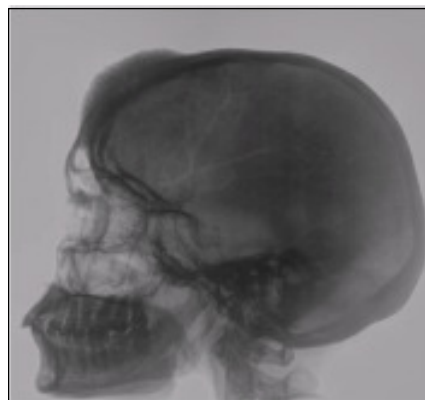


Fig 2. Showing Photographic Inversion

From the Department of Radiodiagnosis, Dyanand Medical College & Hospital, Ludhiana - 141001- India

Correspondence to : Dr. Paramdeep Singh, 1813, Maharaj Nagar, Near P.A.U Gate 3, Ludhiana-141001, Punjab -India