



## CASE REPORT

# Microfilariae in Testicular Fine Needle Aspiration Biopsy

S. Shamshad Ahmad, Mohd. Jaseem Hassan, Kafil Akhtar,  
S.H. Arif, Mohd. Naim, Khaliqur Rahman

## Abstract

Filariasis due to *Wucheria bancrofti* is endemic to Southern Asia. While the laboratory diagnosis has been conventionally made by demonstrating microfilariae in peripheral blood smears, these have also been occasionally diagnosed on aspiration cytology of various organs. This paper reports the finding of microfilariae in material obtained from the testicular mass in an eighteen year old male by fine needle aspiration (FNA) cytology.

## Key words

Testis, microfilaria, aspiration biopsy

## Introduction

An estimated 90-150 million people world wide are infected with microfilarial species and more than 90% by *W. bancrofti* (1). Filariasis due to *Wucheria bancrofti* is endemic to Southern Asia. While the laboratory diagnosis of filariasis have been conventionally made by demonstrating microfilariae in peripheral blood smear, these have also been occasionally diagnosed by cytological study of the material obtained by fine needle aspiration of various organs. Literatures reveal occasional reports of microfilariae found in variety of locations including thyroid (2), soft tissue (3), bone marrow (4), epididymis (5), lung (6), bronchoalveolar fluid (7), breast (8), gastric brushing (9) and hydrocele fluid (10). Here we report a case of bilateral testicular enlargement in which fine needle aspiration cytology revealed microfilariae.

## Case Report

An eighteen year old male presented with bilateral testicular enlargement since 3 years. He had a history of fever for 10 days accompanied by sudden increase in testicular size during this period, with no history of trauma, anorexia or weight loss. Systemic

examination including the extremities was normal. Examination of the genitalia revealed a large firm left testis (7 x 8 cm) as compared to right testis (6 x 7 cm) with erythema and tenderness. Multiple palpable lymph nodes were noted in bilateral inguinal region with no evidence of hydrocele.

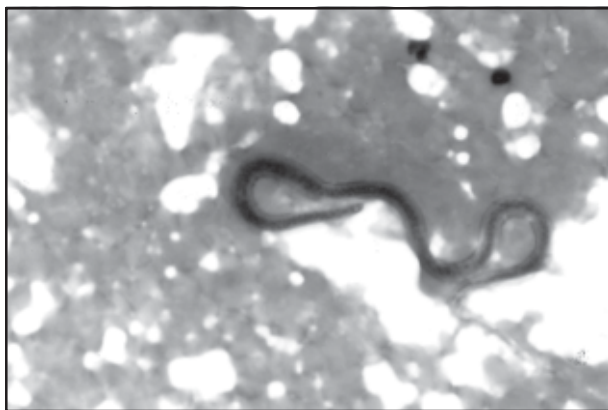
Routine examination of chest, cardiovascular and abdominal cavities revealed no abnormality. Haematological and biochemical parameters were normal except a raised erythrocyte sedimentation rate (36 mm in 1st hr) and mild eosinophilia (Eosinophils - 10%).

## Cytological Findings

FNAB of both testes using a 23 gauge needle was performed after observing standard procedures. The cytologic smears were wet fixed in 95% ethyl alcohol and stained by papanicolaou and H & E stains. The smear from left testis revealed microfilariae identified by presence of a rounded anterior end, hyaline sheath, somatic nuclei and cephalic space (Fig-1). Right testicular smears showed only spermatogenic cells whereas inguinal nodes were reactive in nature.

From the Department of Pathology, JNMC, Aligarh.Muslim.University., Aligarh UP, India.

Correspondence to : Dr. S. Shamshad Ahmad (Professor), Dept. of Pathology, JNMC, AMU, Aligarh (U.P.), INDIA.



**Fig-1: Microfilaria of *W. bancrofti* Showing Rounded Anterior End, Hyaline Sheath, Somatic Nuclei and Cephalic Space (Pap Stain x 400)**

### Discussion

The clinical picture in the present case did not give any clue regarding the etiology of the bilateral testicular enlargement. There was no evidence of lymphoedema or hydrocele. Except for mild eosinophilia and slight high in erythrocyte sedimentation rate, all other investigative parameters were normal. However cytologic examination of the testicular fine needle aspiration revealed microfilariae, while the peripheral blood smear was negative for the organism. This finding does not appear to be unusual because filariasis without microfilaremia has been reported earlier in endemic areas (11). Walter et al (12) reviewing 35 cases of reported microfilariae in cytologic material remarked on the relative rarity of occurrence of microfilariae on smear examination. Recently an Indian study also confirmed that testicular tissue can be also one of the site of adult *Wuchereria bancrofti* (13).

The finding of a microfilariae in the tense testicular swelling in this case was considered incidental as no history of filarial illness was elicited. This supports the observation of Beaver (11) that filariasis may be present without microfilaremia.

Regarding the treatment of such a case is conventional hetrazan and recently doxycycline has been shown to reduces plasma VEGF-C/sVEGFR-3 and improves pathology in lymphatic filariasis (14).

### Conclusion

In bilateral testicular enlargement possibility of filariasis must be kept in mind as one of the possibility and filariasis may be present without microfilaremia, thus FNAC may be useful to reveal microfilariae in such a case.

### References

1. Anupindi L, Saboo R, Rao R, Verghese G, Rao P. Microfilariae in bronchial brushing cytology of symptomatic pulmonary lesion: A report of two cases. *Acta Cytol* 1993; 37: 397-99.
2. Mehrotra R, Lahiri VL, Hazra DK: Microfilariae identified in FNA of a thyroid nodule. *Diagn Cytopathol* 1997; 16: 149-50.
3. Pandit A, Shah R, Shenoy SG. Adult filarial worm in a fine needle aspiration of a soft tissue swelling. *Acta Cytol* 1997; 41: 944-46.
4. Rani S, Beohar PC. Microfilariae in bone marrow aspirate. A case report. *Acta Cytol* 1981; 25: 425-26.
5. Jayaram G. Microfilariae in fine needle aspirates from epididymal lesions. *Acta Cytol* 1987; 31: 59-62.
6. Awasthi R, Jain AP, Swaroop K, Samal N. Bancroftian microfilariasis in association with pulmonary tuberculosis. *Acta Cytol* 1991; 35: 717-18.
7. Halperin D, Fairfax MR, Bedrossian C. *W bancrofti* in BAL fluid. *Diagnostic Cytopathol* 1995; 12: 285-86.
8. Sen Gupta R. Breast filariasis diagnosed by needle aspiration cytology. *Diagn Cytopathol* ; 3: 392-93.
9. Singh M, Mehrotra R, Shukla J, Nigam DK. Diagnosis of microfilaria in gastric brush cytology. A case report. *Acta Cytol* 1999; 43: 853-55.
10. Vassilakos P, Cos JN. Filariasis diagnosed by cytologic examinations of hydrocele fluid. *Acta Cytol* 1974; 18: 62-64.
11. Beaver PC. Filariasis without microfilaremia. *Am J Trop Med Hyg* 1970; 181-89.
12. Walter A, Krishnaswami H, Cariappa A: Microfilaria of *Wuchereria bancrofti* in cytologic smears. *Acta Cytol* 1983; 27: 433-436.
13. Reddy GS, Das LK, Pani SP. The preferential site of adult *Wuchereria bancrofti*: an ultrasound study of male asymptomatic microfilaria carriers in Pondicherry, India. *Natl Med J India* 2004 ;17(4):195-96.
14. Debrah AY, Mand S, Specht S *et al*. Doxycycline reduces plasma VEGF-C/sVEGFR-3 and improves pathology in lymphatic filariasis. *PLoS Pathog* 2006 ;2(9):e92.