



Twin Pregnancy with Large Fibroid

Vijay Khajuria

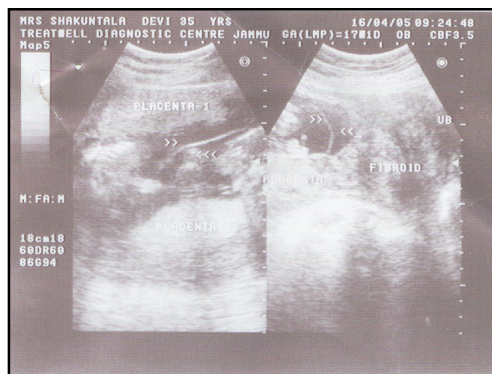


Fig. 1. Showing two separate placenta one anterior and other is posterior. Inter twin membrane (>> <<) is seen with fibroid.

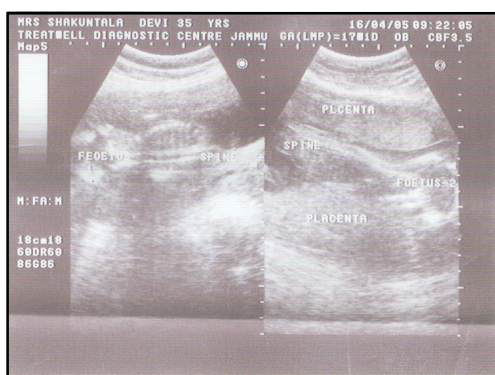


Fig. II. Twin pregnancy with both foetus in transverse lie. Foetus I is having head in right flank & Foetus II head is in left flank.

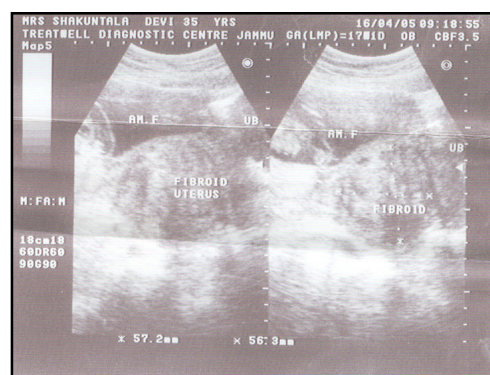


Fig. III. Large fibroid in uterus measuring 57.2 x 56.3 mm with twin pregnancy.

A 35 year old primigravida reported with history of amenorrhoea of 17 weeks duration. Obstetric examination revealed that uterus height was more than the corresponding period of amenorrhoea, ultrasound examination showed twin live pregnancy with both foetus in transverse lie. Both foetus had separate plascenta and gestational age bar 17 weeks one day \pm 10 days (Fig. 1,2). Additionally there was a large size fibroid in the lower uterine segment measuring 57.2 x 56.3 mm (Fig. 3). This case is worth reporting because it is not so easy for women to conceive with such large fibroid as it happened in present case, more so it is rare to have twin pregnancy in such cases.

From the Treatwel Diagnostic Centre, Canal Road, Jammu (J&K) India

Correspondence to : Dr. Vijay Khajuria, Radiologist, 374-A, Gandhi Nagar, Jammu - 180004.