

Localized Orbital Non-Hodgkin's Lymphoma

Imtiyaz Ahmad, Abdul Wahab, Junaid Salam, Reyaz A. Untoo

Abstract

Localized orbital non-Hodgkin's lymphoma is a rare form of extranodal lymphoma, which has not been reported much in the literature. The orbit differs from the rest of the body, excluding the central nervous system, as concerns lymph drainage. This may be possible to explain some of the peculiar features in lymphoid orbital lesions. A localized orbital non-Hodgkin's lymphoma in an elderly man is hereby presented for its entry.

Key words

Non-Hodgkin's Lymphoma, Orbit, Chemotherapy

Introduction

Non-Hodgkin's lymphoma's are a group of neoplasms characterized by proliferation of malignant lymphocytes. Localized orbital non-Hodgkin's lymphoma is a rare form of extranodal lymphoma. The presentation in these cases is usually subtle; there are no overt inflammatory clinical signs such as erythema, chemosis of the conjunctiva, or orbital or ocular pain (1-3). The superior orbit is affected most frequently. Grossly, lymphoid tissue has a creamy, yellow, fish-flesh or reddish appearance, and, because it lacks the fibrous stroma characteristic of inflammatory pseudotumor, it tends to be friable. The extraocular muscles can be involved on very rare occasions (4). When this occurs, the superior rectus-elevator complex is most frequently infiltrated and is enlarged to a much greater extent than what one typically sees in the idiopathic myositis or in the Grave's disease. Unlike idiopathic inflammatory pseudotumor, which presents as multifocal lesions, lymphoid tumors are almost always unifocal.

Case Report

A 65 year old male was referred from a peripheral health centre with a diagnosis of encysted mucocele. The

patient had a 2 year history of swelling near the medial canthus of right eye. The swelling was painless, progressive in size, not associated with erythema or ulceration of the overlying skin (Fig. 1.). There was a history of watering from the right eye of almost same duration, which probably was the reason for the wrong diagnosis of the disease at the peripheral health centre. However, the eye was mildly proptosed and displaced slightly laterally. A FNAC of the swelling revealed a poorly differentiated lymphocytic non-Hodgkin's lymphoma. Computed Tomography (CT) scan of the orbit and brain was done to reveal the extent of orbital involvement and any brain involvement. However, CT orbit revealed a mass occupying mainly the superonasal aspect of the orbit and also extending down below the inferior orbital margin. The medial rectus muscle was free and there was no bony involvement as well. To confirm the FNAC diagnosis, an excision biopsy of the swelling was done. Surgery revealed a well-defined, firm mass extending both superiorly and inferiorly from the nasal aspect of the orbit. Histopathology of the mass confirmed the FNAC finding of a poorly differentiated

From the Department of Ophthalmology, SKIMS Medical College, Bemina, Srinagar, (J&K) India.

Correspondence to : Dr. Imtiyaz Ahmad, Deptt. of Ophthalmology, SKIMS Medical College, Bemina, Srinagar.

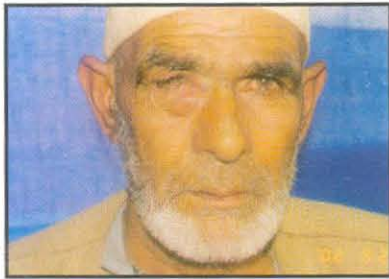


Fig 1. Showing a mass occupying the medial and inferonasal aspect of the orbit displacing the globe slightly outwards.

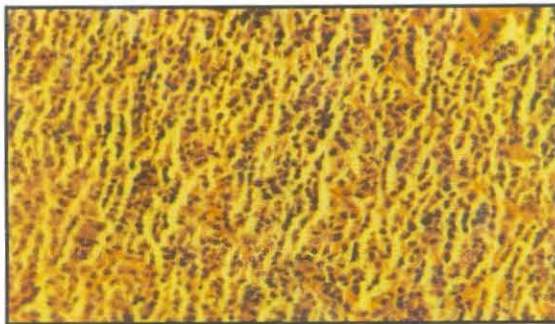


Fig 2. Histopathology of the excised mass showing clusters of large lymphoblasts.

lymphocytic lymphoma of low grade sub-group (Fig. 2). The patient was given chemotherapy and 6 cycles of CHOP regimen (Cyclophosphamide, Adriamycin, Vincristine and Prednisolone) extending over a period of 12 months. The patient has now passed a period of 1 year after chemotherapy without any sign of recurrence or secondary lesion anywhere in the body.

Discussion

The etiology and pathogenesis of non-Hodgkin's lymphoma remain obscure. It has been suggested that lymphomas arise where there is an immunoregulatory defect in the face of a persistent stimulus to polyclonal lymphocyte stimulation. Supporting this hypothesis is the observation that persons with certain autoimmune diseases, congenital immunodeficiency syndromes and those who have received allografts have an **unusually high incidence** of non-Hodgkin's lymphoma (5-7).

CT Scan has been a useful tool in the diagnosis of orbital lymphomas. Lymphoid tumors of the orbit present a distinctive molding pattern on CT; they mold themselves to the globe and orbital bones and rarely cause bone destruction (8).

It is important to determine the histological features and clinical stages in order to choose the appropriate treatment methods. Rappaport classification divides non-Hodgkin's lymphoma's into sub-groups according to whether the malignant cell is well differentiated, poorly differentiated or histiocytic. The Working Formulation subdivides non-Hodgkin's lymphoma's into low-grade, intermediate-grade and high-grade subgroups, based on their 5 year survival statistics. The low-grade group has 5 year survival rate ranging from 50%-70%; intermediate-grade 35%-45% and high grade 23%-32%.

Traditionally, poorly differentiated low grade lymphomas have not been treated until they produce symptoms. This is because, single-agent chemotherapy or combination of agents do not induce complete remissions and more importantly, they do not change the overall survival of patients. These regimens include the use of single alkylating agents like Cyclophosphamide or Chlorambucil or combinations like CVP (Cyclophosphamide, Vincristine and Prednisolone) or CHOP (CVP plus Adriamycin)

References

1. Jakobiec FA. Orbital inflammations and lymphoid tumors. Symposium on disease and surgery of the lids, lacrimal apparatus and orbit. Transactions of the new Orleans Academy of Ophthalmology. St. Louis, Missouri, CV Mosby 1982; pp 52-85.
2. Jakobiec FA, McClean I, Front R. Clinicopathological characteristics of orbital lymphoid hyperplasia. *Ophthalmology* 1979; 86 : 948-66.
3. Jakobiec FA. Lymphoid tumors (Pseudotumor, pseudolymphoma, reactive lymphoid hyperplasia, malignant lymphoma). In Frauenfelder F (ed) : Current ocular therapy. St. Louis, CV Mosby 1980 ; pp 257-80.
4. Hornblass A, Jakobiec FA, Reifler DM *et al*. Orbital lymphoid tumors located predominantly within extraocular muscles. *Ophthalmology* 1987; 94 : 688-97.
5. Lukes R, Collins R. Immunologic characteristics of human malignant lymphomas. *Cancer* 1974; 34 : 1488-1503.
6. Hansen JA, Good RA. Malignant disease of the lymphoid system is immunological perspective. *Hum Pathol* 1974; 5 : 567-99.
7. Louie S, Daust PR, Schwartz RS. Immunodeficiency and the pathogenesis of non-Hodgkin's lymphoma. *Semin Oncol* 1980; 7 : 267-84.
8. Yoe JH, Jakobiec FA, Abbott GF, Trokel SL. Clinical and computed tomographic diagnosis of orbital lymphoid tumors. *Am J Ophthalmol* 1982; 94 : 235-45.