

Usefulness of Ilizarov's Procedure in Infected Non-union of Tibia and Femur

R.K. Arora

Abstract

A total of 46 patients with infected diaphyseal non-union of tibia (38) and femur (8) were subjected to Ilizarov's ring fixator. Thirty six cases were of infected nonunion with gap requiring bone transport (Group I) while 10 cases did not require bone transport (Group II). In majority of group I cases unifocal corticotomies were done through metaphyses of the bone. In two cases, where the gap was large, bifocal corticotomies were done in tibia to shorten the treatment time. Controlled distraction was begun after 7 day's time. Normotrophic regenerate was observed in all cases except one case of tibia and one femur. Both these cases required cancellous bone grafting. In group II, six cases of infected non-union of tibia and four of infected femur required only radical debridement and acute compression at the fracture site. Failure of union was seen only in two cases. Forty four patients showed union clinically and radiologically with a success rate of 95.4%. Equinus contracture (mild) and toe drop were seen in one case of group I. Average follow up is of 67 months. Average distraction at corticotomy site was 60 mm. Average time for fixator removal was 239 days.

Key words

Ilizarov's procedure, Bone transport, Distraction, Infected nonunion

Introduction

Infected nonunion with or without gap is one of the difficult orthopedic problems. This gap may be because of bone loss in open fractures or excision of infected bone ends by the surgeon. Various procedures for infected nonunion have been tried but these were often unsuccessful. If at all the bone united, shortening remained a problem. Ilizarov's controlled distraction at the corticotomy site, producing new bone in the gap thus created, revolutionized the treatment of gap nonunion (1,2). Thus the shortening and the non union, both, are

addressed at the same time. Now most of the cases show acceptable bony union, reasonably good function and equal limb length.

Experience of Ilizarov's apparatus and its usefulness in infected nonunion of tibia and femur both is presented here in this article.

Material and Methods

Forty six cases who came for management of infected non-union of femur/ tibia (between January 1993 and August 2000) have been divided into two groups:

From the Department of Orthopedics, SGRD Institute of Medical Sciences and Research, Amritsar, Punjab.

Correspondence to : Dr. R.K. Arora, Consultant Orthopedic Surgeon, 36-Anand Avenue, Amritsar Punjab-143 001.

Group I: Infected non-union with a bony defect (gap) where bone transport was required (36 cases).

Group II: Infected non-union without any leg length discrepancy (10 cases).

A careful pre operative planning for construction of the Ilizarov's ring fixator was done. The fixator was applied under general/spinal anaesthesia in the standard manner (2,3). The wires were tensioned with the dynamometric wire tensioner. Where gap was up to 3 centimeters, acute shortening and closure of the gap was done. Here lengthening was done through the coricotomy site. Where gap was >3 cms, gap was shortened up to three cms. Rest of it was covered by bone transport (Figure 1). The corticotomies were done through metaphyses (upper or lower) in all cases. In two cases of tibia, bifocal corticotomies were done to shorten the treatment time. The non-union site, after compression/

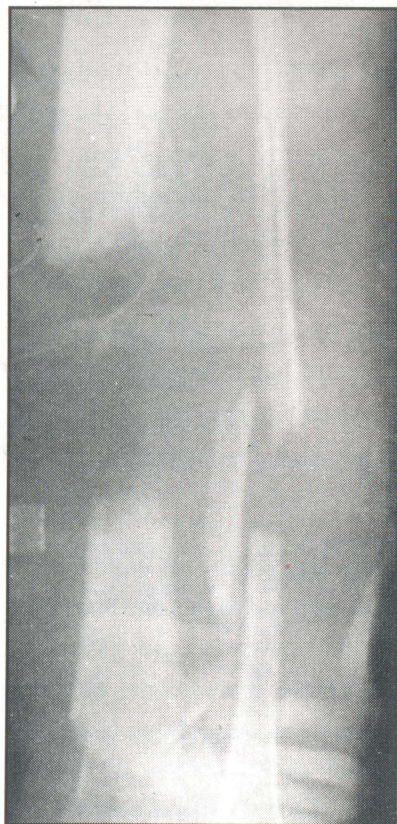


Fig 1. Showing the gap in tibia.

docking, was freshened in all cases. If gap/shortening was > 5cms, the lowermost ring was fixed to the indigenous equinus prevention device (4). Patient was advised active exercises of toes and other free joints immediately after the effect of anaesthesia was over. Crutch walking with gradually increasing weight bearing was started after a week.

Controlled distraction was started after seven days. After another week, x-rays were taken to see whether bone ends were actually getting distracted (Fig.2). To see the regenerate, x-rays were taken after a further period of three/four weeks. Patients were taught fixator care, physiotherapy and technique of distraction. Then they were discharged with the advice to maintain contact with the surgeon at least twice a month.

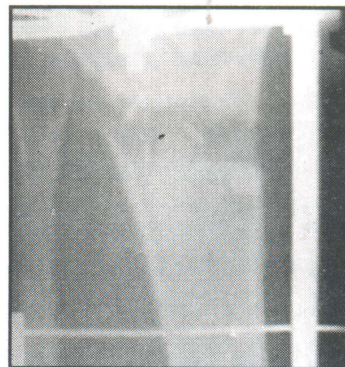


Fig 2. Shwoing the gap after ten day's distraction.

The type and adequacy of regenerate and the time it took to consolidate along with the status of non-union were studied radiologically. It was also studied whether graduated distraction could be done every eight hours instead of every six hours as advocated by Ilizarov(2). The remodeling of the regenerate was critically evaluated by skiagrams.

When non union site was bridged with callus and the differentiation of the regenerate into cortex and medullary canal were visible in the regenerate (Fig.3), dynamization of the fixator was done and axial loading of the limb permitted for a couple of days before fixator removal.

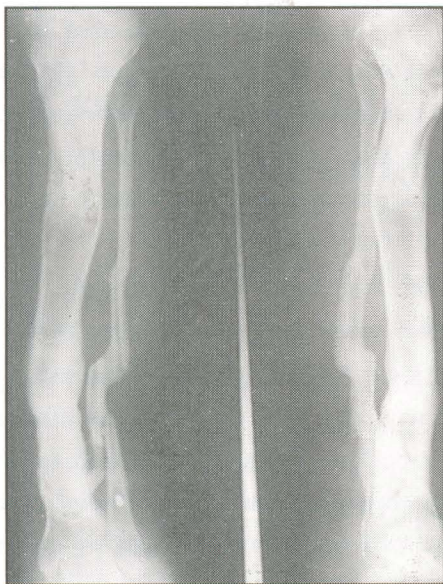

Fig 3. Showing mature regenerate & union at the time of removal of the fixator.

Results

Average age of the series was 35 years with the range being 24-58 years.

Group I: Out of 36 cases in this group, 32 were of infected non-union of tibia and four of femur.

Group II: Out of ten cases, six were of infected non-union of tibia and four of femur.

Most patients could be made to bear weight with crutches within one week of operation. In all, except two cases, corticotomy was done through one metaphysis. In two cases, bifocal corticotomy was done. Hybrid fixator was applied in all cases of femur. Corticotomies done through lower metaphyses of femur gave better results. In two cases of femur, corticotomies were done through upper metaphyses and both these cases had problems. One case did not unite (there was no LLD). Second case had severe, intractable pain and abandoned the treatment midway.

Controlled distraction was started after seven days of application of the fixator and was done every six hours in

30 cases and every eight hours in the remaining cases. The regenerate was normotrophic in all except two cases where cancellous bone grafting had to be done.

Bony union was achieved in 44 cases (96.65 %) at an average of 239 days. Average distraction at corticotomy site was 60mm. (range being from 30mm. to 120mm.). Superficial infection at the skin pin interface was there in almost 30% of these sites. No equinus contracture resulted in any case thanks to the procedure adopted in long bone transportation cases.

In group I cases, sound bony union was achieved in all cases. In this group, hammer toe deformity resulted in two toes of one case who had also developed mild equinus and it had to be corrected with flexor tenotomy and capsulotomy of the IP joints of the toes. Infection and draining sinuses persisted in six cases. One case had sequestrum visible on x-rays and it had to be removed to cure the discharging sinus. Two failures were there.

One case of femur in group II went on to "unite" on x-rays. Fixator was removed and the patient allowed walking with the help of walker. Patient came after three months with characteristic non-union on x-rays. He did not submit himself to operation again.

Second case, again of femur, left treatment midway because of severe, intractable pain. There were two broken wires, which had to be replaced. There were eight loose wires, which had to be retensioned. Pain was tolerable even if with the help of analgesics in 45/46 cases.

Discussion

In group I-the leg length was equalized. On docking, the compression applied to this site leads to crushing and metaplasia of the interposed soft tissues and results in bony union. It is better if we freshen the docking site and still better if we apply cancellous bone graft. This was also the approach of Paley D, *et al.* (5). Otherwise the pain of crushing of soft tissues is very severe, sometimes unbearable as was evident from the case of femur that

left treatment midway.

Most of my cases had one to four (average 2.1) operative procedures before they submitted themselves to the Ilizarov's procedure. This average was 2 in another series (4).

Distraction every eight hours has been found to be as effective as the one done every six hours in this series. Similar findings were also reported by Dube *et al.*(6). Bifocal Corticotomy resulted in shorter duration of treatment as was demonstrated by two cases in this series. The regenerate at both the sites in tibia, in both the cases, was normotrophic. No equinus contractures developed because in both cases, the equinus prevention brace had been applied. This approach is better than fixing calcaneus with one or two wires (3,7).

Male preponderance in this series is perhaps because of more outdoor activities of males. Average external fixation time was 16 months (5) and eight months (8) in other series whereas it was 239 days in this series. The average distraction was 100 mm, 83 mm and 60 mm in these three series respectively.

Infection was eradicated in 38 out of 46 cases. Toh & Jupiter (9) reported eradication of infection in 35 out of 37 cases of tibia and Paley *et al* (5) in all of their cases of tibia.

In all the cases, final leg length discrepancy was negligible, so was it in the series of Marsh *et al* (10) who had compared the results of conventional techniques with those of bone transport in infected non-unions of tibia.

Functional results were excellent in 15/46, good in 16/46, fair in 13/46 and poor in 2/46 cases. These were excellent in 12/19, good in 6/19 and poor in 1/19 cases in the series of Paley *et al* (5). Theirs were certainly better

results, may be it is the learning curve in the present series.

This procedure has been found to be reliable with predictable results in tibia cases. Femur cases are difficult for many reasons. The application of the fixator in exact axis is important in femur. But it is equally difficult. It is felt that corticotomy in femur should be done through lower metaphysis for better results. Cost of fixator can be minimized, as most of the components are reusable. The only disadvantage of the Ilizarov's external fixator is the lengthy fixation time (5).

References

1. Cattaneo R, Catagni M, Johnson EF. The treatment of infected non union & segmental defects of tibia by method of Ilizarov. *Clin Orthop* 1992; (280) : 143-52.
2. Ilizarov GA. Modern techniques in limb lengthening; Clinical application of the technion-stress effect for limb lengthening. *Clin Ortho Rel Research* 1990; 250:8-26.
3. Catagni M. Non-union of leg (tibia)-Bianchhi A, Aronson J. (Eds) Operative Principles of Ilizarov-ASAMI group. Milan Italy, Williams & Wilkins 1991; 199-244.
4. Arora RK. An indigenous way to prevent equinus in long limb lengthening. *Ind J Ortho* 2002; 36(1): 59-60.
5. Paley D, Maar DC. Ilizarov Bone transport treatment for tibial defects. *J Ortho Trauma* 2000; 14 (20) : 76-85.
6. Dubey A S, Aggarwal RP, Kumar A, Singh M. Outcome of infected diaphyseal non-union treated by Ilizarov's method. *Ind J Ortho* 1999; 33(4): 253-55.
7. Paley D. Problems, obstacles & complications of limb lengthening. *Clin Orthop India* 1991; 6: 152-73.
8. Song HR, Cho SH, Koo KH, Jeong ST, Park YJ, Ko JH. Tibial bone defects treated by internal bone transport using Ilizarov's method. *Int Orthop* 1998; 22(5): 293-97.
9. Toh CL, Jupiter JB. The infected non union of the tibia. *Clin Orthop* 1995; 315: 176-91.
10. Marsh JL, Prokusi L, Biermann JS. Chronic infected tibial non-union with bone loss. Conventional techniques versus bone transport. *Clin Orthop* 1994; 301 : 139-46.