

Neurilemmomas of Parapharyngeal Space

Padam Singh Jamwal, Gajan Singh, Sunil Kotwal, Kuldeep Singh*,
Ashok Sharma, Vijay Gupta

Abstract

Neurilemmomas are rare neurogenic tumours. Their parapharyngeal location is uncommon. Three patients of neurilemmomas of this location are described. Different modes of presentation, radiological findings and management of these cases are discussed.

Key Words

Neurilemmoma, Neurogenic tumour, Parapharyngeal tumours

Introduction

Neurilemmomas are among the less common solitary tumours of head and neck. Since they arise from neurilemmal sheath of the peripheral, cranial and sympathetic nerves, they are widely distributed in the body. Neurilemmomas of parapharyngeal space may arise from any of the last four cranial nerves or autonomic nerves in this area, primarily vagus and cervical sympathetic chain (1). Because of deep seated location, the lesions involving parapharyngeal space present a great difficulty to the clinician as for their pre-operative assessment and specific technique of surgery (2). Keeping in view the rarity, interesting clinical and radiological findings, we describe three cases of neurilemmomas of parapharyngeal space.

Case 1.

A 45 year old male attended E.N.T. out-patient department, with a swelling on the left side of the neck for last 1 year. Three months before presenting to us, the patient had undergone an unsuccessful attempt at removal of tumour at another hospital, following which he developed hoarseness of voice. The histopathology of the excised tissue showed only normal lymphnode tissue. Local examination revealed a firm, mobile, nonpulsatile, swelling measuring 4cm x 4cm

with diffuse margins, involving the left submandibular region. It extended from anterior border of sternomastoid to middle of ramus of mandible. Upper border of the swelling was inaccessible. Oral examination did not reveal any swelling. Examination of nose and nasopharynx did not show any abnormality. Indirect laryngoscopy revealed left vocal cord palsy. There was no other cranial nerve involvement. The routine laboratory work up was within normal limits. X-ray of the chest and base of the skull did not show any abnormality. Fine needle aspiration cytology (FNAC) was nondiagnostic. CT scan of neck with contrast enhancement revealed a moderately enhancing left parapharyngeal mass (Fig. 1).

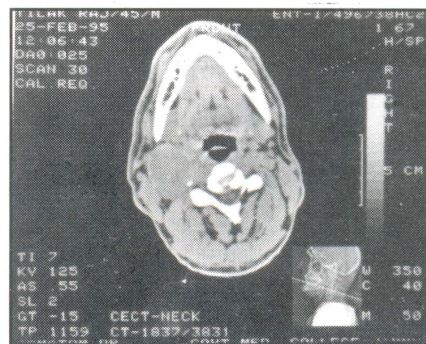


Fig. 1. CT Scan showing left parapharyngeal mass.

From the Postgraduate Departments of ENT & *Pathology, Government Medical College, Jammu (J&K)

Correspondence to : Dr. Padam Singh Jamwal, Lecturer, Department of ENT, Government Medical College, Jammu-180001 (J&K) India.

The tumour was completely excised through a left inframandibular cervical incision. No connection of the tumour with any cranial nerve could be demonstrated. Post operative recovery was uneventful. The histopathological examination of tumour mass showed it to be neurilemmoma (Fig. 2). Follow-up after more than one year did not reveal any evidence of tumour recurrence.

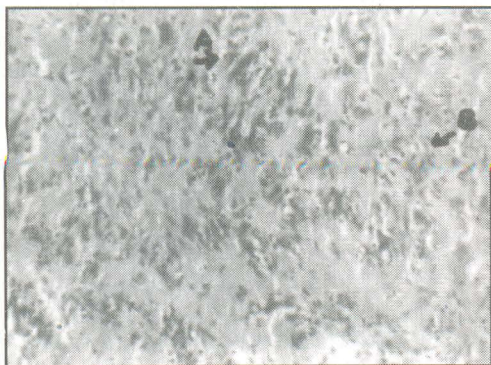


Fig. 2. Photomicrograph showing Antoni A & Antoni B areas (x200) H&E stain

Case 2

A 20-years old male was referred to us with history of a painless progressively growing lump on the right side of the neck for the last two years. Patient denied any symptoms of dysphagia, dyspnoea, cough or syncope. On examination, his voice was normal. There was a smooth, firm, nontender, nonpulsatile, irreducible swelling in the right side of neck extending from anterior border of upper third of sternomastoid to 1 cm from midline (Fig. 3). The lower end of the swelling was at the level of upper border of thyroid cartilage. The upper border of the swelling was not palpable as it was extending upwards under the ramus of the mandible. The skin over the swelling was normal. One large vessel each was palpable on the lateral and anteriomedial border of tumour. There was no bruit over the swelling. Examination of the pharynx revealed a bulge on the right lateral wall of pharynx just behind the right posterior tonsillar pillar, extending from the level of vallecula to above the level of hard palate. Mucosa over the swelling was intact and freely mobile. The swelling was bimanually palpable. Carotid angiography showed splaying of carotid fork with internal carotid artery displaced laterally and external carotid artery

anteriomedially. The tumour vascularity was, demonstrated (Fig. 4). Contrast CT scan demonstrated a well encapsulated, irregularly enhancing right parapharyngeal space mass with central necrosis (Fig. 5). With a tentative diagnosis of neurilemmoma, the mass was explored through a curved right upper cervical incision made at the level of hyoid bone extending from mastoid tip upto the midline. The bifurcation of carotid was exposed, and the encapsulated tumour mass was found. Hypoglossal nerve was lying on the surface of the tumour from which it was separated. The tumour was pushing internal carotid artery laterally and external carotid artery antero-medially. It was separated from both the arteries and carotid fork. The tumour was removed intact. Histopathology proved it to be a case of neurilemmoma. The patient developed right sided hypoglossal palsy postoperatively. After one year of follow up there is no tumour recurrence but the hypoglossal palsy persists.

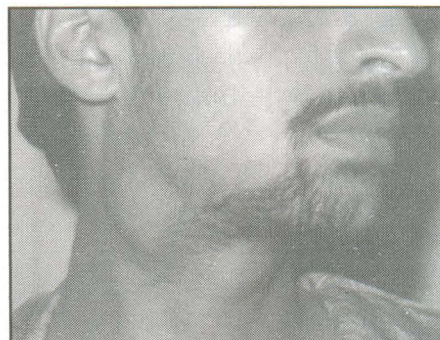


Fig. 3. Showing swelling in the right side of the neck.

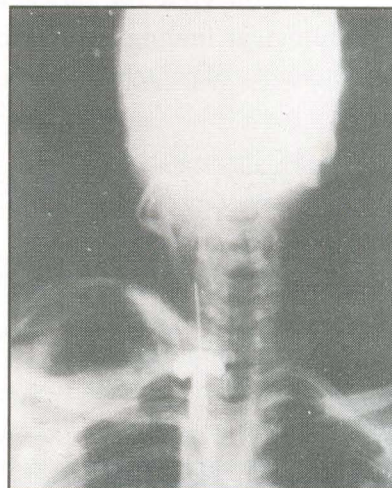


Fig. 4. Carotid angiography showing splaying of carotid fork and displacement of internal carotid artery laterally.

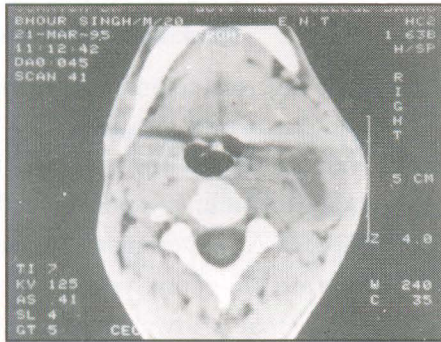


Fig. 5. CT scan showing irregularly enhancing right parapharyngeal mass with central necrosis.

Case 3

A 28 years old male presented with complaints of change in voice and mass on the left side of throat of 3-months duration. He noticed the mass only after change in voice. There was no history of dysphagia or dyspnoea. Local examination revealed a bulge on the left pharyngeal wall extending from behind the posterior tonsillar pillar to almost midline. This was extending from the level of floor of vallecula to above the level of hard palate. The mass was 5cm. × 3cm., firm, non-tender and nonpulsatile. Mucosa over the mass was intact and freely mobile. There was no external swelling. Examination of nose, ear and larynx did not reveal any abnormality. There was no cranial nerve palsy. A transoral FNAC was non-confirmatory. CT scan of neck with contrast enhancement revealed a moderately enhancing, well encapsulated, left parapharyngeal mass (Fig. 6). Using an external approach, the patient was explored under general anaesthesia. The left submandibular gland was removed to gain a wide access to the upper pole of the tumour. A well encapsulated mass was dissected out. Histopathology confirmed it as a case of neurilemmoma. No connection with any of the cranial nerves was demonstrated. The patient developed Horner's syndrome in the post-operative period. There occurred a bluish discoloration and oedema of pharyngeal mucosa on the operated side which disappeared in a few days. There is no evidence of tumour recurrence on one year of follow-up but the Horner's syndrome persists.

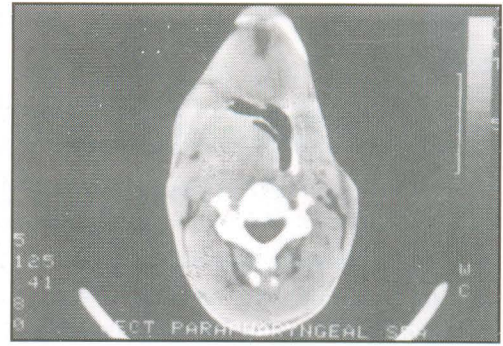


Fig. 6. CT scan showing left parapharyngeal mass.

Discussion

The tumours arising from neurilemmal sheath are known as Schwannomas or neurilemmomas. Grossly, the neurilemmoma presents as a solitary, firm, encapsulated mass. In the parapharyngeal space, the tumours are diagnosed when they are of considerable size because of their deep seated location. Most of the neurilemmomas are initially asymptomatic and usually present with a swelling in the pharynx or externally or both. The parapharyngeal space is a potential space with three rigid walls so that the growth of a tumour in the region proceeds either medially or inferior or both. The pattern of growth accounts for distinctive clinical appearance of a displaced palate and pharynx (3). Pain is uncommon whereas dyspnoea, dysphagia, a vague discomfort or a sensation of pressure occur as late symptom with large tumour (4). Similar presentation has been seen in our cases. Although, we have observed hoarsness of voice because of left vocal cord palsy in Case 1, it was due to previous surgery as an additional symptom. The "plummy voice" seen in one of our patient (Case 3) was because of bulge in the oropharynx and was a late symptom. The neurilemmomas are said to be the most common contrast enhancing tumours of the parapharyngeal space. Since areas of haemorrhage or cystic degeneration can occur, some tumour areas may not enhance. This irregular enhancement seen on CT scan may actually suggest the diagnosis (1). Similar CT findings were observed in one

of our cases, (Case 2) which predicted the probable histological diagnosis.

The type of displacement of arteries depends upon nerve of origin and also whether the tumour arises near the base of skull or near the medial portion of parapharyngeal space. The usual finding seen in these cases is displacement of internal carotid artery either anteriorly or medially. An unusual displacement of internal carotid artery with splaying of carotid fork was seen on carotid angiography in case 2. Because of this particular vascular arrangement seen on angiography, a preoperative diagnosis of carotid body tumour was considered. However absence of tumour blush on angiography, moderately enhancing well encapsulated tumour with central necrosis seen on CT scan suggested a diagnosis of neurilemmoma.

The probable histological nature of the tumour in this area is the most important criteria for the particular surgical approach (2). Although aspiration biopsy has been suggested to be a convenient and expedient way to resolve this problem by Day and Roseler, however, in our cases FNAC was not helpful in reaching at the preoperative diagnosis.

The treatment of the parapharyngeal neurogenic tumours is surgical excision and majority of the workers prefer an external approach (5,6). In all our cases, the tumours were removed through an external approach after making an upper cervical incision at the level of hyoid bone. Excision of submandibular gland in case 3, gave a good visual access to the upper pole of the tumour. No connection of the tumour with cervical sympathetic chain or any other cranial nerve could be demonstrated. Horner's syndrome and hypoglossal nerve palsy occurred in one case each. Since the hypoglossal palsy developed on the 7th postoperative day, it might have been due to nerve involvement by healing process. On regular follow-up, till date, there is no evidence of tumour recurrence. Recurrence has not be reported even if a part of capsule is left behind (7).

Conclusion

Neurilemmomas are less common solitary tumours of head and neck. Most are initially entirely asymptomatic and usually present with swelling in the pharynx, externally or both. Dyspnea and dysphagia occur as late symptom. An experienced cytopathologist is required to reach at a pre-operative diagnosis. It is the advent of CT scan that allows a more systematic **preoperative evaluation to determine which tumour requires preoperative angiography**, to find the size and extent of tumour, to differentiate between parotid and extraparotid masses and in many cases, suggests the probable histopathology. An external approach is recommended for removal of neurilemmomas of parapharyngeal space by most authors, so that important structures are well visualised and are not damaged. Anterior displacement or removal of submandibular gland improves the access to upper pole of the tumour. Furthermore, even intracapsular excision of these has not been associated with increased risk of recurrence.

References

1. Som PM, Biller HF, Lawson W. Tumours of parapharyngeal space : Preoperative evaluation, diagnosis and surgical approaches. *Ann Otol Rhinol* 1981 (Suppl) ; 90(4) : 3-15.
2. Mehra YN, Mann SBS, Dubey SP, Verma A, Suri S. Pre-operative assessment of parapharyngeal tumours. *Ind J Otol* 1989 ; 41 : 43.
3. Work WP, Hybels RL. A study of tumours of parapharyngeal space. *Laryngoscope* 1974 ; 84 : 1748-55.
4. Anand CC, Maru YK, Pooroy VK. Neurilemmoma of the parapharyngeal space. *Ind J Otol* 1979 ; 31 : 117.
5. Gore Don O, Rankow R, Hanford JM. Parapharyngeal neurilemmoma. *Surg Gynae Obstt* 1956 ; 103 : 193.
6. Bradenberg JH. Neurogenic tumours of parapharyngeal space. *Laryngoscope* 1972 ; 82 : 1292.
7. Krag KV, Soule EH, Masson JK. Benign and malignant neurilemmoma of the head and neck. *Surg Gynae Obstt* 1960 ; 111 : 211.