

Post-Injection Gluteal Fibrosis: A Neglected Problem

Naseer Ahmed Mir, Sheikh Manzoor Ahmed*, Javeed Ahmed Bhat

Abstract

A series of eleven cases of post injection gluteal fibrosis is presented manifesting with varying degrees of disability in late childhood. Discussion includes review of literature and a plea is made for prevention of the condition.

Key words

Fibrosis, Skeletal muscle, Post-injection

Introduction

Fibrosis of skeletal muscle following intramuscular injection is an iatrogenic condition. The prevalence has increased conspicuously since the advent of antibiotic therapy. It has most commonly been reported in quadriceps muscle when outer aspect of the thigh has been chosen as a convenient site for intramuscular injection and also it has frequently been reported in deltoid muscle (1). Reports of sporadic cases of gluteal fibrosis came mainly from Spain and other Mediterranean countries (2-7). Since the muscle is frequently a site of injection, the paucity of reports on gluteal fibrosis is difficult to explain. The cases are presented to add to the list of this problem. The habit of repeated and indiscriminate use of intramuscular injections is prevalent especially in the rural areas of the state of Jammu & Kashmir. Some degree of post injection gluteal fibrosis and neurological impairment is missed especially in young children because it usually takes several years to manifest before it presents clinically (1,5).

Material and Methods

Between the year 1990 and 2001, the authors had the opportunity to study eleven cases of post injection fibrosis of gluteal muscles. History of repeated intramuscular injections was obtained from these patients. Patients were divided into rural or urban category. Detailed systemic and local examination was done. Local examination of the buttocks for number of dimples, atrophy and fibrosis of underlying gluteal musculature was performed. Range of movements especially at the hip joints was measured. Examination was also done for any deformity. All the patients were subjected to radiograph of pelvis including hip joints.

Results

A series of 11 cases of post injection gluteal fibrosis is presented, with varying degrees of disability due to gluteal fibrosis. There were 7 females and 4 males with age ranging from 9 to 17 years (average 13 years). In all cases there was history of repeated intramuscular injections in their early childhood for some febrile illnesses.

From the Departments of Orthopaedic Surgery and *Dermatology, SKIMS Medical College, Bemina, Srinagar, J&K.

Correspondence to : Dr. Naseer Ahmad Mir, Consultant, Department of Orthopaedic, SKIMS Medical College, Bemina, Srinagar, J&K.

Among eleven children 7 belonged to rural areas of the valley while 4 belonged to urban society. The 8 children had minor degrees of disability with restriction of some terminal degrees of flexion and adduction of hip and had minor degrees of scarring of buttocks. Among these 4 had unilateral involvement. They all reported for some difficulty in squatting. The other 3 children had multiple dimples in both buttocks with atrophy and fibrosis of underlying gluteal musculature. They had marked restriction of flexion and adduction of both hips resulting in difficulty in squatting (Fig 1 & 2). Radiography of pelvis

with both hip joints was normal. A possible improvement with surgical intervention by division of fibrotic bands, myotomy with or without lengthening of tendons was proposed for 3 cases with marked degree of fibrosis but they refused to undergo surgical intervention.

Discussion

There are numerous reports in the literature of fibrosis and contracture of the skeletal muscle. The most of literature is on fibrosis and contracture of quadriceps (1,8-12) and deltoid musculature (1,2,11,13,14). Following injection into the deltoid muscle in childhood, the earliest finding is the appearance of a dimple overlying the muscle and gradually an adduction deformity of the shoulder develops over the course 4-5 years. The majority of children respond to surgical intervention of division of fibrotic band of deltoid and/or division of shortened tendinous bands of the adjoining muscle fibres.

Gluteal musculature although a frequent site of injection, the paucity of reports on gluteal fibrosis is difficult to explain (1,3-7). Shanmugasundaram reported only six cases of gluteal fibrosis in the age group of 10 months to 8 years in his personal series of 169 cases of post injection muscular fibrosis including 4 cases of bilateral gluteal fibrosis. 2 cases of unilateral contracture were operated with only full correction achieved in one case and partial correction in another(1). Post injection gluteal fibrosis occurs more frequently than is believed and if this fact is borne in mind when dealing children from 4 to 6 years of age, presenting with abnormal gait, an early diagnosis can be made. If diagnosed early, the lesion can be treated successfully by physiotherapy alone while advanced cases need Z-lengthening of the tendons (7).

Piero A. *et. al.* reported 5 cases of gluteal fibrosis and proposed intramuscular injection as a possible etiological factor (6). Because of involvement of only small number of children in a country like Spain where use of intramuscular injection is so common. He suggested

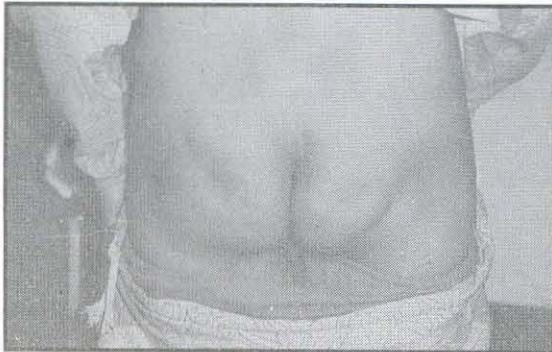


Fig. 1: Clinical photograph showing puckered dimples of both buttocks due to fibrosis of underlying gluteal muscles.

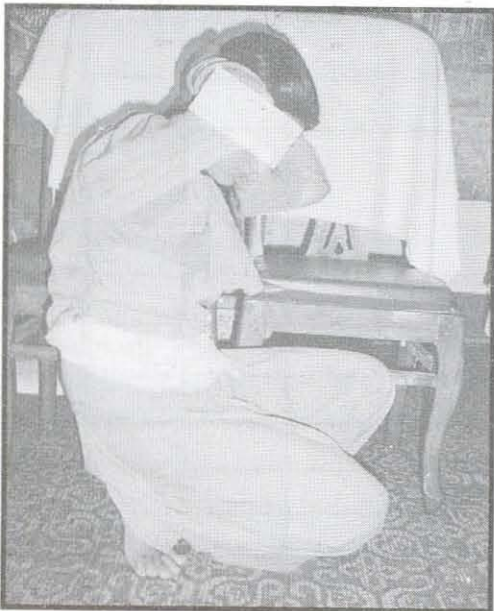

Fig 2: Photograph showing difficulty in squatting due to restriction of flexion and adduction of both hip joints.

that some other factor might also be playing a role. Chen *et. al.* reporting a series of injection myopathy with deltoid and/ or gluteal fibrotic contracture found that repeated injection injuries and myotoxicity results in multifocal myositis as the first trigger of the fibrotic syndrome and abnormal control of collagen formation could be another important pathogenic factor (2). Napiontek and Ruszkowski reported 8 children of paralytic foot drop and gluteal fibrosis after intramuscular injection (5). The gluteal fibrosis was not diagnosed until 5.1 years after the injection while sciatic nerve palsy presenting as equinus or equinovarus deformity was diagnosed on an average of 3.8 months after the intragluteal injections.

It is also evident from the study of literature that gluteal fibrotic contracture becomes manifest only after a gap of several years and thus it is important to draw attention to the potential complication caused by indiscriminate use of intramuscular antibiotics.

References

1. Shanmugasundaram TK. Post injection fibrosis of skeletal muscle: A clinical problem. A personal series of 169 cases. *International Orthopaedics (SICOT)* 1980 ; 4(1) : 31-37.
2. Chen SS, Chien CH, Yu HS. Syndrome of deltoid and / or gluteal fibrotic contracture: an injection myopathy. *Acta Neurol Scand* 1988; 78(3): 167-76.
3. de Valderrama JAF. A cause of limited flexion and adduction of the hip in Children. Proc. B.O.A. Meeting, Sept. 1969, *Br J Bone Joint Surg* 1970 ; 52 : 179.
4. Duran Sacristan H, Sanchez Barba A, Lopez-Duran Stern I, *et. al.* Fibrosis of gluteal muscles. *Am J Bone Joint Surg* 1974 ; 56(7) : 1510-19.
5. Napiontek M, Ruszkowski K. Paralytic drop foot and gluteal fibrosis after intramuscular injections. *Br J Bone Joint Surg* 1993 ; 75(1) : 83-85.
6. Peiro A, Ferandez CI, Francisco G. Gluteal fibrosis. *Am J Bone Joint Surg* 1975 ; 57(7) : 987-90.
7. Viladot A, Motta A, Viladot R, Callea C. Gluteal fibrosis. *Ital J Orthop Traumatol* 1976 ; 2(2) : 239-46.
8. Bose K, Chong KC. The clinical manifestation and pathomechanics of contracture of the extensor mechanism of the knee. *Br J Bone Joint Surg* 1976 ; 58 : 478.
9. Fairbank TJ, Barrett A.M. Vastus intermedius contracture in childhood. *Br J Bone Joint Surg* 1961 : 43 : 326.
10. Gammic WFP, Taylor JH, Urich H. Contracture of vastus intermedius in children. *Br J Bone Joint Surg* 1963 ; 45 : 370.
11. Hill NA, Liebler WA, Wilson HJ, Rosenthal E. Abduction contracture of both glenohumeral joints and extension contracture of one knee secondary to partial muscle fibrosis. A case report. *Am J Bone Joint Surg* 1967 ; 49 : 961-64.
12. Williams PF. Quadriceps contracture. *Br J Bone Joint Surg* 1968 ; 50 : 278.
13. Bhattacharyya S. Abduction contracture of the shoulder from contracture of the intermediate part of the deltoid. Report of three cases. *Br J Bone Joint Surg* 1966 ; 48 : 127-31.
14. Rolodoo R., Warren D. Abduction deformity of the shoulder secondary to fibrosis of the central portion of the deltoid muscle. In: Proc. of the American Academy of Orthopaedic Surgeon. *Am J Bone Joint Surg* 1972 ; 54 : 1332.