

Accessory Soleus Muscle : A Case Report and Review of the Literature

Naseer Ahmed Mir, Khurshid Ahmed Kangoo

Abstract

A rare case of accessory soleus muscle presenting as equines deformity with mild cavus of right ankle is reported.

Key Words

Accessory soleus muscle.

Introduction

Accessory soleus muscle is a supernumerary leg muscle that is rare and usually clinically silent. Most of the cases reported so far have been associated with symptomatology(1,2). Though congenital in origin, it manifests in the second and third decade of life as a soft tissue mass due to muscle hypertrophy. A case of accessory soleus muscle with equines deformity of ankle is presented.

Care report

A 12 year old boy reported with equines deformity of right ankle with mild cavus. He became aware of the deformity for last few years only. Detailed examination did not reveal any contributory factor for his equines deformity. When patient was explored for performing lengthening of tendo achilles, an aberrant soleus muscle was found along medial aspect of soleus inserting into calcaneus through a separate tendon (Fig. 1). This aberrant muscle had muscle belly almost extending upto calcaneous. The tendon of this aberrant muscle was also lengthened to achieve correction of equines deformity.

Steindler's procedure for release of plantar fascia and muscles near calcaneous was also done for correction of mild degree of cavus deformity.

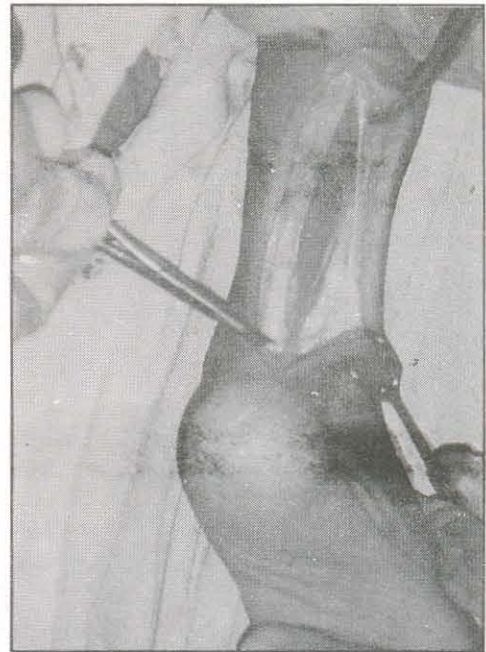


Fig 1: Operative photograph of medial aspect of ankle showing accessory soleus muscle on medial aspect of the tendoachille's with its muscle belly extending almost upto calcaneous

From the Department of Orthopaedics, Sher-i-Kashmir Institute of Medical Sciences, Medical College Hospital, Srinagar, (J&K).
Correspondence to: Dr. Naseer Ahmed Mir, P.O. Box 940, GPO Srinagar-190001 (J&K), India.

Discussion

Accessory soleus muscle is a rare anatomic variant and usually presents as a soft tissue mass on postero-medial aspect of the ankle. Cadaveric studies have demonstrated the incidence of an accessory soleus muscle from 0.7-5.5% (3). They usually remain clinically silent and magnetic resonance imaging is the preferred study for the diagnosis of this condition. It must be considered in the differential diagnosis of soft tissue mass in the postero-medial region of the ankle like ganglion, lipoma, hemangioma, synovioma and sarcoma.

If patient is asymptomatic and diagnosis of accessory soleus muscle is made, only observation is recommended. If symptomatic, fasciotomy or excision is recommended (3). One should be aware of this condition when interpreting CT or MRI of the ankle, which shows characteristic findings of a normal muscle in an abnormal location (1,3,5,6,7).

In the present case the accessory soleus muscle was an accidental finding found during tendoachilles

lengthening for equines deformity of the ankle. Both tendoachilles and tendon of the accessory soleus had to be lengthened to achieve correction. It is quite possible that this aberrant muscle had contributed to the development of equines deformity.

References:

1. Doker G, Linclau LA. Case report: the accessory soleus muscle: symptomatic soft tissue tumour or accidental finding. *Neth J Surg* 1981 ; 33(3) : 146-49.
2. John MM, Borrelli AH. Asymptomatic accessory soleus muscle. *J Foot Ankle Surg* 1999 ; 38(2) : 150-53.
3. Brodie JT, Dormans JP, Gregg JR, Davidson RS. Accessory soleus muscle. A report of 4 cases and review of literature. *Clin Orthop* 1997 ; 337 : 180-86.
4. Downey MS, Siegeman J. Accessory soleus muscle: a review of the literature and case report. *J. Foot Ankle Surg* 1996 ; 35(6) : 537-43.
5. Palaniappan M, Rajesh A, Rickett A, Kershaw CJ. Accessory soleus muscle: a case report and review of the literature. *Pediatr Radiol* 1999 ; 29(8) : 610-12.
6. Travis MT, Pitcher JD. Accessory soleus presenting as posterior ankle mass: a case report and review of the literature. *Foot Ankle Int* 1995 ; 16(10) : 651-54.
7. Vanek J, Fourre D. Accessory soleus muscle. *Acta orthop Belg* 1993 ; 59(4) : 401-03.

Products :

- Syp. **FAROCID**
- Cap. & Syp. **LYRONE**
- Cap. **XEROCID (20)**
- Tab. **KALICET**
- Tab. **FAMONAC-MR**
- Tab. **CIFROX (500)**

For further details please contact :

M/S MEGHA-POOJA MEDICAL AGENCIES (C&F)

F/17, Shiv Nagar behind A. G. Office, Jammu, J&K.

Stockist : Bee Kay & Co.

Raghunath Bazar, Jammu, J&K.

