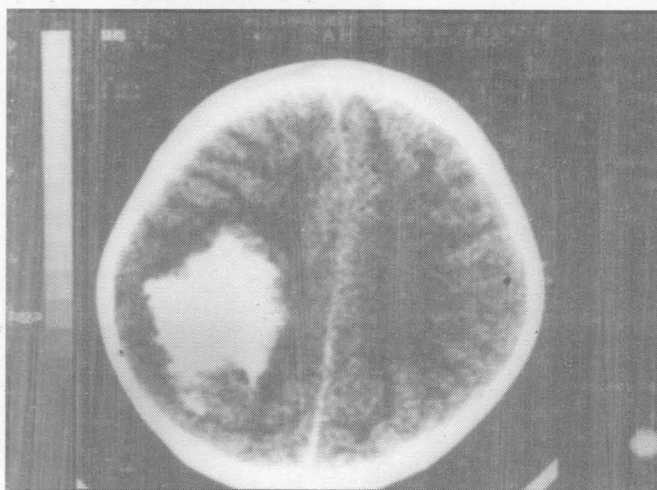




## Snow Ball like Intracranial Calcification

S. K. Gupta, Vijay Kumar Verma, M. L. Babu\*, Annil Mahajan



*CT scan of the brain of a 4-year old child showing massive right parietal lobe calcification*

Intracranial calcification is seen in a variety of disorders like tumours, haematomas, physiological conditions and metabolic disorders. Massive lobar calcification has been seen in meningiomas, oligodendrogliomas and astrocytomas.

Our patient, a 4-year old child presented with focal motor seizures of left upper limb. She was put on anticonvulsants and discharged. One month later, she reported with Epilepsia Partialis Continua. On examination, she had grade four weakness of left upper limb. Fundus was normal. On investigations, all biochemical parameters including serum calcium was normal. Her CT scan of the brain showed massive right parietal calcification with surrounding oedema. She was given anti-oedema measures and Injection Dilantin. She is on oral phenytoin now and is on follow up with no focal neuro-deficit.

From the Postgraduate Department of <sup>†</sup>Neurology and <sup>\*</sup>General Surgery, Govt. Medical College, Jammu (J&K) India.  
Correspondence to : Dr. S. K. Gupta, <sup>†</sup>Neurologist, Government Medical College, Jammu (J&K) India.