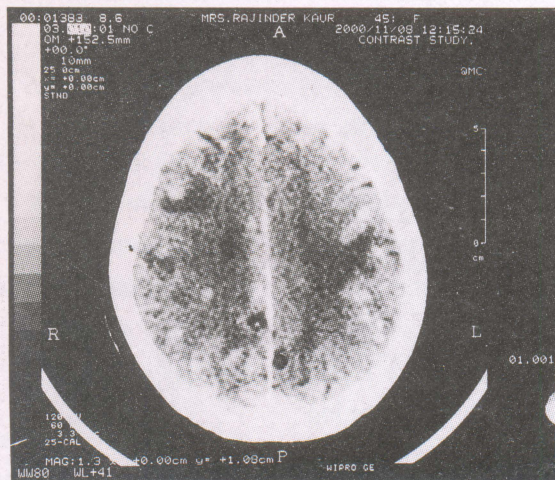




## Neurocysticercosis presenting as Encephalitis like Illness

S. K. Gupta, Vijay Kumar Verma, Annil Mahajan, Ashok Parihar



*CT scan of brain showing multiple extensive parenchymal neurocysticercosis with calcified and active lesions with perifocal edema. The bright central spots in the lesions represent the proteoscolex within the cysts.*

Neurocysticercosis occurs when the cysticerci develop within the brain predominantly at the gray and white matter junction. The central nervous system involvement occurs in 50-70% of all cases. A variety of clinical syndromes have been described including epilepsy, raised intracranial pressure, meningo-encephalitis, chronic meningitis, focal neurological deficit, stroke like illness, hydrocephalous, vasculitis, cranial nerve palsies and psychiatric symptoms. The commonest presentation of neurocysticercosis is seizures, affecting about 36 to 42% of subjects.

Our patient, a female aged 45 years, presented with encephalitis-like illness having headache, vomiting and unconsciousness of 12 hours duration. She was normotensive and in coma grade I with bilateral papilloedma and there was no neck rigidity. The biochemical parameters were within normal limits. But after the CT scan of the brain, the patient was diagnosed as neurocysticercosis and treated with steroids and albendazole. She regained consciousness on 4th day, did not have any neurodeficit and was discharged on anticonvulsants. Encephalitis-like illness is a rare occurrence with neurocysticercosis but in areas where cysticercosis is common, one must consider it as one of the causes of coma.

From the Neurology Section, Postgraduate Department of Internal Medicine, Government Medical College, Jammu (J&K) India.  
Correspondence to : Dr. S. K. Gupta, Consultant Neurologist, Government Medical College, Jammu (J&K) India.