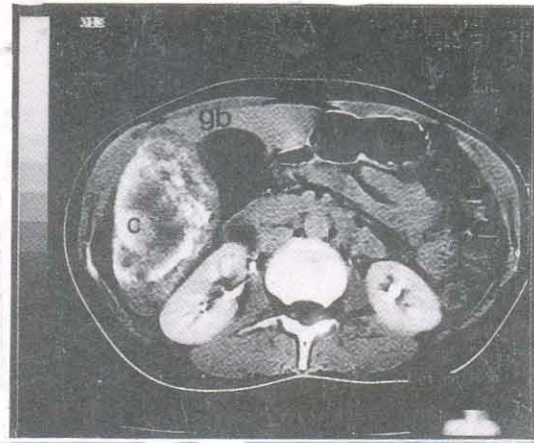
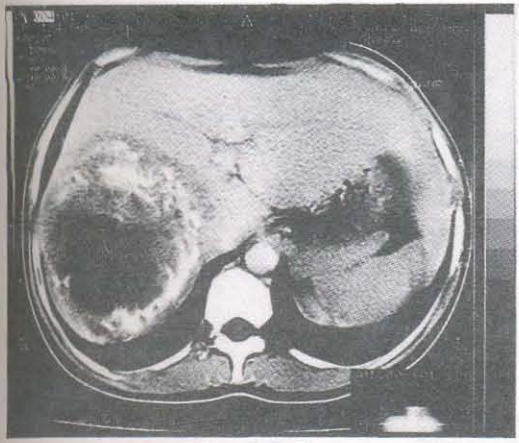


Calcified Hydatid Presenting as Mucocele of Gallbladder

Nasib C. Digray, Gurjit Singh, Yogeshwar Mengi, H. L. Goswamy



'B'

CT scan films showing a large calcified hydatid cyst in right lobe of liver (A). Part of the calcified cyst is extending around/engulfing the cystic duct to produce mucocele of gallbladder (B).

Calcification is one of the common complication of liver hydatids, occurring in 14% of cases. Although most of the calcified cysts remain asymptomatic, some may present with features of non-resolving pneumonia, pseudocholelithiasis or gastric outlet obstruction. A review of literature reveals that surgery for complicated calcified hydatid carries a higher mortality/morbidity as compared to other complications. Our patient presented with mucocele of gallbladder and required a cholecystectomy.

From the Department of Surgery, Government Medical College, Jammu (J&K) India.

Correspondence to : Dr. Nasib C. Digray, Consultant Pediatric Surgeon, Govt. Medical college, Jammu (J&K) India.